

Postlaminectomy instability–is fusion essential in degenerative lumbar stenosis surgery?

 Güven Gürsoy

Muğla Sıtkı Koçman University, Faculty of Medicine, Neurosurgery Department, Muğla Turkey

Cite this article as: Gürsoy G. Postlaminectomy instability–is fusion essential in degenerative lumbar stenosis surgery? J Health Sci Med 2022; 5(6): 1732-1735.

ABSTRACT

Aim: To examine the incidence of postlaminectomy instability in cases of lumbar spinal stenosis who underwent facet-preserving laminectomy and decompression with the classical laminectomy technique, together with comorbid diseases, and to determine whether fusion is needed.

Material and Method: The patients who were operated by the same surgeon in the same hospital between 2017 and 2019 and followed up in terms of instability in the postoperative 1st and 6th months were evaluated retrospectively with their clinical findings, comorbid diseases and radiological images. White and Panjabi's instability criteria were used. It was analyzed with SPSS 23.00 statistical package program. Data were analyzed by descriptive statistics (number, percentage distribution, mean and standard deviation), t-test and ANOVA.

Results: A total of 53 patients, 22 male (41.5%) and 31 female (58.5%) were included in the study. Age, surgical procedures and comorbid diseases were investigated. None of the patients, but 2 patients with osteoporosis with or without diabetes, had postlaminectomy instability.

Conclusion: It has been shown in our study that decompressive and facet-preserving surgery performed at 2 levels or less using only the classical laminectomy technique does not cause instability in patients without osteoporosis alone or with diabetes, especially in the first 6 months, and can be safely applied to patients. Osteoporosis alone or in association with diabetes mellitus suggests increased postoperative instability.

Keywords: Decompression, laminectomy, spinal stenosis

INTRODUCTION

Degenerative lumbar stenosis is the most common disease in the aging spine. Surgical decompression is effective and important in the treatment of neurogenic claudication, but the effect and necessity of fusion surgeries are not as clear as decompression surgeries in the literature. Postlaminectomy instabilities are a common reason for reoperation after decompression procedures. Posterior transpedicular stabilization and fusion surgery to be performed in addition to laminectomy reduces the risk of instability, but increases the duration of surgery, increases morbidity and mortality rates, increases the rates of interventional complications, may cause adjacent segment disease in the long term, and increases the financial burden of health services. In the literature, in which cases fusion is necessary and in which cases it is not, different results are published in different series.

The aim of this study is to retrospectively examine the incidence of postlaminectomy instability in cases of

lumbar spinal stenosis who did not have preoperative instability, who underwent facet-preserving laminectomy and decompression with the classical laminectomy technique, considering comorbid diseases, and to evaluate whether fusion is required in addition to laminectomy in these patients.

MATERIAL AND METHOD

The study was conducted with the permission of the Muğla Sıtkı Koçman University Clinical Researches Ethics Committee (Date: 08/08/2019, Decision No: 09/V). All procedures were carried out in accordance with the ethical rules and the principles of the declaration of Helsinki.

The patients who were operated by the same surgeon in the same hospital between 2017 and 2019 and followed up in terms of instability in the postoperative 1st and 6th months were retrospectively analyzed with clinical findings and radiological images.

Laminectomies up to 2 levels, flavectomy and foraminotomies were performed in these patients who were operated in the prone position under intratracheal general anesthesia with the classical laminectomy technique. Patients with instability on preoperative dynamic radiographs, those who underwent more than bilateral 1/3 medial facetectomy, those who underwent surgery in 3 or more level functional vertebral segments, patients who did not have at least 6 months of follow-up, and patients without demographic data and radiological imaging were excluded from the study. Orthoses or corsets were not used in any of the patients in the postoperative period in order to preserve functional movement. Radiological instability was evaluated according to Panjabi and White's instability criteria, by comparison with preoperative and postoperative (1st and 6th months) 2-way lumbosacral radiographs (neutral AP and neutral lateral) and functional lumbosacral vertebral radiographs (lateral hyperflexion and lateral hyperextension). More than 5 millimeters of translation and/or more than 15 degrees of angulation in a functional segment was considered as radiological instability and postlaminectomy instability.

Statistical Analysis

All records and data of the patients were analyzed with SPSS 23.00 statistical package program. Data were analyzed by descriptive statistics (number, percentage distribution, mean and standard deviation), t-test and ANOVA. Parameters that were determined not to show normal distribution were compared using the Mann-Whitney U test. The findings were evaluated at 95% confidence interval and 5% significance level.

RESULTS

A total of 53 patients, 22 male (41.5%) and 31 female (58.5%) were included in the study. In both sexes, the mean age was 61.1887 ± 11.14081 (41-86), and the median age was 68. The mean duration of the surgical procedure was 60.47 minutes (44 – 96 minutes). It was seen that 25 patients had 1 level (47.2%) and 28 patients had 2 level (52.8%) total laminectomy. Surgical site infection was not observed in any patient. When the comorbid diseases of the patients are examined; 21 (39.6%) patients had no additional disease, 12 (22.6%) patients had only hypertension, 8 (15.1%) patients had hypertension and diabetes, 4 (7.5%) patients had only diabetes, 3 (5.7%) patients had diabetes and osteoporosis, 2 (3.8%) patients had only coronary artery disease, 2 (3.8%) patients had coronary artery disease and diabetes, and 1 (1.9%) patient had only osteoporosis (Table 1, 2, 3).

Table 1. Demographic data

Sex	n	%
Male	22	41.5
Female	31	58.5
Total	53	100.0

Table 2. Patient age, operation time and number of laminectomy level(s)

	Patient Age (years)	Operation Time (min)	Number of Laminectomy Level(s)
Average	65.1887	60.4717	1.5283
Median	68.0000	68.0000	2.0000
Standard deviation	11.14081	21.53673	0.50398
Min	41.00	44.00	1.00
Max	86.00	96.00	2.00

Table 3. Comorbid disease(s)

Comorbid disease(s)	n	%
No	21	39.6
Diabetes	4	7.5
Hypertension	12	22.6
Coronary artery disease	2	3.8
Hypertension and diabetes	8	15.1
Osteoporosis	1	1.9
Diabetes and osteoporosis	3	5.7
Coronary artery disease and diabetes	2	3.8
Total	53	100.0

Panjabi and White's radiological instability criteria were used in the evaluation of instability by AP, lateral, hyperflexion and hyperextension radiographs in the 1st and 6th months postoperatively. More than 5 millimeters of translation and more than 15 degrees of angulation in a vertebral functional segment were considered as radiological instability and postlaminectomy instability. Accordingly, no radiological instability was observed in the postoperative 1st month. In the 6th month postoperatively, instability was detected in 3 patients (Table 4).

Table 4. Comparison of presence of postoperative instability with parameters

	Postoperative 6 th month instability presence		P value
	Yes (n:3)	No (n:51)	
Gender (%)			0.258
Male	-	23/51 (%44)	
Female	3/3 (100%)	28/51 (%56)	
Age (average)	71,33±6,50	65.14±11,06	0.888
Additional disease (%)	100 %	58 %	0.001*
Number of laminectomy level(s) (%)			0.173
1 level	-	25/51 (50%)	
2 levels	3/3 (100%)	25/51 (50%)	
Follow-up time / month (average)	26±12,4	20±21,99	0.374

* p < 0.05

There was no statistically significant difference between gender, age, laminectomy level(s), duration, and instability development at the postoperative 6th month ($z=-1.203, -0.140, -1.349, -0.888$, respectively; $p=0.229, 0.888, 0.177, 0.374$) according to the Mann-Whitney U test. When the relationship between the presence of comorbidity and the development of instability at the postoperative 6th month was examined, a statistically significant difference was found ($p=0.017, z=-2.236, U=5.0$) (Figure).

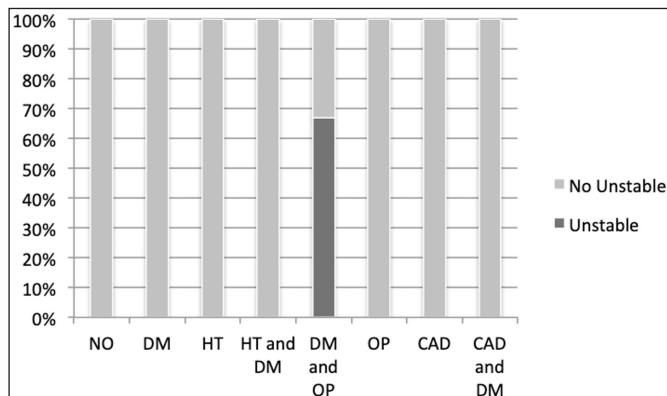


Figure. Comorbid diseases and instability rates

DM: diabetes mellitus, HT: hypertension, OP: osteoporosis, CAD: coronary artery disease

Logistic regression testing was performed to determine the effects of age, gender, operative level(s), postoperative duration, and comorbidities on patients' probability of postoperative instability. Hosmer-Lemeshow goodness-of-fit statistical test p values were found to be >0.05 (H-L statistics=6.82, $p=0.559$). In the logistic regression model, postoperative instability variance was 47% (Nagelkerke R^2) and adjusted classification was 94.3%. Osteoporosis alone or in association with diabetes mellitus was associated with increased postoperative instability (respectively; RR: 1.59, 95% CI: 1.31-3.98, p -value: 0.047, and RR: 1.90, 95% CI: 1.54-12.10, p -value: 0.003).

DISCUSSION

It has been shown in our study that decompressive and facet-preserving surgery performed at a distance of 2 levels or less, using only the classical laminectomy technique, did not cause instability in patients without osteoporosis or diabetes and osteoporosis coexistence, especially in the first 6 months.

Symptomatic lumbar spinal stenosis leads to progressive neurogenic claudication, radicular pain and loss of strength. Surgical interventions may be required to relieve pain, eliminate limitation of movement, and improve quality of life. Variable degrees of disc herniations, hypertrophies and cyst formations in the zygoapophyseal facet joints, and hypertrophy of the ligamentum flavum play a role in the pathoanatomical causes of this disease.

Neural stenoses that cause central canal stenosis cause neurogenic claudication, and stenoses that occur in lateral recession cause radiculopathies. Surgical indication is mainly due to neurological deficits or unresponsiveness to conservative treatments.

Instability is defined as the loss of the ability of the spine not to damage and irritate the spinal cord under physiological loads, in addition to deformity and structural changes, and loss of mobility (1). White and Panjabi (2) described that sagittal plane translation 4.5 mm on flexion-extension radiographs or translation between two vertebral bodies greater than 15% of the vertebral body, or sagittal plane rotation greater than 15° at L1-L2, L2/L3 or L3/L4 levels determined that it is more than 20° , at the L4/L5 level and more than 25° , and at the L5/S1 level as radiological instability criteria.

Among decompressive techniques, laminectomy is considered as the gold standard surgical treatment. Although the short-term results and benefits of laminectomy in lumbar spinal stenosis have been studied in detail, the concerns about iatrogenic instability and the appropriate indications for concomitant fusion have been ongoing for a long time (3).

Basically, fusion surgeries are recommended in cases of degenerative spondylolisthesis or dynamic instability (4). Laminectomy and facetectomy performed in decompression surgery can lead to overt and iatrogenic instability. Postlaminectomy instabilities are a common reason for reoperation after decompression procedures. This risk is minimized in minimally invasive techniques and facet preserving interventions. In our study, cases without preoperative instability were included, and the effect of facet-sparing surgeries on comorbid diseases was examined. In terms of postlaminectomy instability, lower rates were obtained than in the literature.

Post-laminectomy deformity is the clinical and radiological expression of loss of resistance of the posterior elements to traction forces, whether or not associated with insufficient capacity to support the anterior portion of the spinal column. Occasionally, it may result in progressive deformity accompanied by neurological deficit due to compression of the nerve tissues within the spinal canal. Deformities after laminectomy are seen relatively early. It has been stated that postoperative immobilization will not prevent the appearance of deformity, but may delay the deformity (5).

Although the facet joints are often preserved during laminectomy, the lamina, interspinous, supraspinous, and flavum ligaments are cut and/or removed. All of these structures have stabilizing functions for the spinal motion segment. Removal of these structures can lead to clinical spinal instability, defined as an increase in range of motion

(ROM), spinal stiffness leading to reduced physiological conditions, and/or neurological disturbances through reduction in ultimate spinal strength and nerve root compression, deformation such as scoliosis or spondylolisthesis, and/or pain (2). Currently, there are no strict rules about when additional instrumentation should be added (6,7). The biomechanical effects of a single-level lumbar laminectomy and additional instrumentation and adjacent segment effects are not yet known precisely (8,9). After laminectomy, it is possible that the rotational stability will decrease with the weakening of the posterior elements, which are soft and bony tissues, which are responsible for axial rotation (10-12). Although torsional forces have been studied in untreated lumbar spines, studies related to torsional biomechanics of laminectomy are limited (13, 14).

It has been reported that, as an alternative to laminectomy, bilateral laminotomy provides adequate and safe decompression of the spinal canal in patients with lumbar stenosis, improves the quality of life by reducing the symptoms of the patients, has similar neurological outcomes, a lower incidence of complications and complications, and a similar iatrogenic instability rate (15).

In our study, facet preserving classical laminectomy to be performed up to 2 levels for patients with osteoporosis or without diabetes and osteoporosis; It has been shown that it can be safely applied to patients, considering it reduces symptoms, provides neural decompression, and the risk of developing iatrogenic instability. Examination of laminectomy performed in more segments and longer follow-up period can be considered as limitations of the study.

CONCLUSION

In conclusion, there is literature information supporting both techniques in terms of classical laminectomy or classical laminectomy combined with fusion surgery. It is obvious that it will be more appropriate to determine a patient-specific surgical treatment by combining the appropriate patient, the appropriate indication and the appropriate surgical technique, and the treatment modalities will be re-examined as biomechanical studies increase and spine biomechanics are better understood.

ETHICAL DECLARATIONS

Ethics Committee Approval: The study was conducted with the permission of the Muğla Sıtkı Koçman University Clinical Research Ethics Committee (Date: 08/08/2019, Decision No: 09/V).

Informed Consent: Because the study was designed retrospectively, no written informed consent form was obtained from patients.

Referee Evaluation Process: Externally peer-reviewed.

Conflict of Interest Statement: The authors have no conflicts of interest to declare.

Financial Disclosure: The authors declared that this study has received no financial support.

Author Contributions: All of the authors declare that they have all participated in the design, execution, and analysis of the paper, and that they have approved the final version.

REFERENCES

1. White AA, 3rd, Johnson RM, Panjabi MM, Southwick WO. Biomechanical analysis of clinical stability in the cervical spine. *Clin Orthop Relat Res* 1975; 109: 85–96.
2. White AA, Panjabi MM. *Clinical biomechanics of the spine*. Philadelphia: Lippincott; 1990. pp. 23–45.
3. Mosenthal WP, Dickherber JL, Saitta BH, Lee MJ. Post laminectomy instability. *Semin Spine Surg* 2019; 31: 100713.
4. Resnick DK, Watters WC III, Sharan A, et al. Guideline update for the performance of fusion procedures for degenerative disease of the lumbar spine. Part 9: lumbar fusion for stenosis with spondylolisthesis. *J Neurosurg Spine* 2014; 21: 54–61.
5. Lutz FS, Munhoz da Rocha LS. Post-Laminectomy Deformities. *Coluna/Columna* 2014; 13: 279-81.
6. Fox MW, Onofrio BM. Indications for fusion following decompression for lumbar spinal stenosis. *Neurosurg Focus* 1997; 3: e2.
7. Herkowitz HN, Kurz LT. Degenerative lumbar spondylolisthesis with spinal stenosis. A prospective study comparing decompression with decompression and intertransverse process arthrodesis. *J Bone Joint Surg Am* 1991; 73: 802-8.
8. Radcliff KE, Kepler CK, Jakoi A, et al. Adjacent segment disease in the lumbar spine following different treatment interventions. *Spine J* 2012; 13: 1339-49.
9. Reeves NP, Narendra KS, Cholewicki J. Spine stability: the six blind men and the elephant. *Clin Biomech* 2008; 22: 266-74.
10. Adams MA, Roughley PJ. What is intervertebral disc degeneration, and what causes it? *Spine* 2006; 31: 2151- 61.
11. Farfan HF, Cossette JW, Robertson GH, Wells RV, Kraus H. The effects of torsion on the lumbar intervertebral joints: the role of torsion in the production of disc degeneration. *J Bone Joint Surg Am* 1970; 52: 468-97.
12. Gordon SJ, Yang KH, Mayer PJ, Mace AH, Jr, Kish VL, Radin EL. Mechanism of disc rupture. A preliminary report. *Spine* 1991; 16: 450-6.
13. Adams MA, Hutton WC. The relevance of torsion to the mechanical derangement of the lumbar spine. *Spine* 1981; 6: 241-8.
14. Farfan HF. Effects of torsion on the intervertebral joints. *Can J Surg* 1969; 12: 336-41.
15. Pietrantonio A, Trungu S, Famà I, Forcato S, Miscusi M, Raco A. Long-term clinical outcomes after bilateral laminotomy or total laminectomy for lumbar spinal stenosis: a single-institution experience. *Neurosurg Focus* 2019; 46: E2.