

Dermatological manifestations and drug-induced reactions in COVID-19 patients: an observational study from İstanbul, Türkiye

 Gökhan Kaya¹,  Didem Dizman²,  Özlem Su Küçük³

¹Department of Dermatology, Nizip State Hospital, Gaziantep, Türkiye

²Department of Dermatology, Faculty of Medicine, Bezmialem Vakıf University, İstanbul, Türkiye

Cite this article as: Kaya G, Dizman D, Su Küçük Ö. Dermatological manifestations and drug-induced reactions in COVID-19 patients: an observational study from İstanbul, Türkiye. *J Health Sci Med.* 2024;7(5):555-563.

Received: 01.07.2024

Accepted: 08.09.2024

Published: 27.09.2024

ABSTRACT

Aims: The systemic and respiratory clinical manifestations of coronavirus disease 2019 (COVID-19) include fever, cough, sneezing, sore throat, rhinitis, dyspnoea, chest pain, malaise, fatigue, anorexia, and headache. Moreover, cutaneous manifestations have been observed in 0.2% to 20.4% of cases. This investigation further explores the dermatological manifestations associated with COVID-19 and reactions induced by its pharmacological treatments. Conducted at a university hospital, the study examined 841 patients and identified skin manifestations in 1.5% of cases. It differentiates between symptoms directly attributed to the viral infection and those arising from treatment, highlighting the need for clinical vigilance and adaptability in managing these manifestations. COVID-19 has been linked to a wide range of clinical symptoms, extending beyond the well-known respiratory effects to include various dermatological manifestations. These manifestations, which range from mild rashes to severe conditions like vasculitis, may complicate diagnosis and management, particularly when similar symptoms are induced by therapeutic drugs used in COVID-19 treatment.

Methods: This cross-sectional study included 841 patients treated in the COVID-19 outpatient and inpatient units of the university hospital between March and May 2020. The assessment involved clinical examinations and telemedicine consultations, focusing on differentiating between viral and drug-induced dermatological reactions.

Results: Dermatological manifestations were observed in 1.5% of the 841 patients. Direct virus-related skin changes were noted in 1% (n=8) of patients, including maculopapular eruptions (50%, n=4) on the face and trunk, trunk-localized urticaria (25%, n=2), and purpuric lesions (12.5%, n=1) on the lower extremities. Drug-induced dermatological reactions were identified in 0.5% (n=5) of patients, featuring conditions such as bullous drug reactions, psoriasiform drug eruptions, hypertrichosis, and urticaria.

Conclusion: These findings highlight the complex interplay between COVID-19 and its treatment, where both the virus and pharmacological agents can trigger significant dermatological reactions. The need for healthcare providers to consider both viral and drug-induced factors in the diagnosis and management of skin manifestations in COVID-19 patients is underscored. Further studies are essential to refine treatment protocols and reduce adverse dermatological outcomes.

Keywords: COVID-19, SARS-CoV-2, cutaneous manifestations, dermatology, pharmacological treatments, skin reactions

INTRODUCTION

COVID-19, caused by the SARS-CoV-2 virus, was first identified in Wuhan, China. The World Health Organization (WHO) declared the COVID-19 outbreak a pandemic on March 11, 2020. The first case was reported in Türkiye on March 10, 2020. As of October 29, 2021, there have been approximately 245 million confirmed cases of COVID-19 worldwide, with over 4.9 million fatalities (WHO, 2021). The ongoing global COVID-19 pandemic, caused by the novel coronavirus SARS-CoV-2, has manifested not only with well-known respiratory symptoms but also with a broad spectrum of dermatological manifestations. These skin-related symptoms have become an area of intense research due to their varied presentations and implications for diagnosis and management. Skin manifestations linked

to COVID-19 include but are not limited to chilblain-like lesions, maculopapular eruptions, urticaria, vesicular rashes, and petechiae. These dermatological signs have been observed in a diverse patient population, appearing sometimes as the initial presentation of the disease, which can precede hallmark respiratory symptoms.^{1,2}

Research suggests that these cutaneous manifestations could stem from the immune response of the body to the virus or vascular damage associated with the disease. The appearance of these skin symptoms in conjunction with, or even before, respiratory symptoms underscores the need for healthcare providers to recognize these presentations for timely diagnosis and isolation of patients.³

Corresponding Author: Gökhan Kaya, gkhnkya@gmail.com



This work is licensed under a Creative Commons Attribution 4.0 International License.

Moreover, treatment strategies employed to manage COVID-19, including the use of hydroxychloroquine, antivirals, and antibiotics, have been associated with adverse cutaneous reactions. These reactions range from mild, such as erythema, to severe life-threatening conditions like Stevens-Johnson syndrome and toxic epidermal necrolysis. The interplay between drug-induced skin reactions and viral skin manifestations poses a significant challenge for clinicians, necessitating a high degree of suspicion and clinical acumen to differentiate between the two.⁴

This study aimed to explore the complex interactions between the virus, host immune response, and impact of therapeutic agents, focusing on the dermatological aspects of COVID-19. Understanding these interactions is crucial for developing effective management strategies and improving the outcomes of COVID-19 patients.

METHODS

Ethical Considerations

The study protocol was reviewed and approved by the Bezmialem Vakif University Ethics Committee (Date: 01.07.2024, Decision No: 155793), ensuring compliance with the ethical standards of the Declaration of Helsinki.

Study Design and Setting

This cross-sectional study was conducted at a tertiary care hospital's COVID-19 outpatient clinic, inpatient wards, and dermatology clinic between March 4, 2020, and May 15, 2020. The hospital, being a major referral centre for infectious diseases, was well-equipped to manage the complexities of COVID-19, providing a suitable environment for the collection of clinical data related to both respiratory and dermatological manifestations. The inclusion of the dermatology clinic allowed for specialized evaluation and classification of cutaneous symptoms, helping to differentiate between viral-induced and drug-induced skin reactions. The study focused on identifying and classifying cutaneous symptoms that arose during the course of infection or as a result of therapeutic interventions, leveraging the expertise of both COVID-19 and dermatology departments for comprehensive patient care.

Participants

A total of 841 patients, both suspected and confirmed COVID-19 cases, were prospectively enrolled in the study. The inclusion criteria were based on the WHO guidelines, with confirmed COVID-19 diagnosis established through clinical symptoms, positive SARS-CoV-2 test results (PCR), and, where necessary, computed tomography (CT) imaging to support diagnosis. CT imaging was particularly used in cases where PCR results were inconclusive or delayed, providing additional diagnostic clarity through characteristic lung changes associated with COVID-19. Patients without clear diagnostic evidence were included if they displayed a strong clinical suspicion of infection based on symptoms and imaging. Exclusion criteria involved patients with pre-existing dermatological conditions unrelated to COVID-19 or those on chronic medications known to cause dermatological side effects.

Data Collection

Data collection was systematic and comprehensive, capturing detailed patient information including demographics (age, sex, underlying health conditions), clinical history (pre-existing skin conditions, medications, and other comorbidities), and COVID-19 symptoms (respiratory, systemic, and cutaneous). Dermatological assessments were carried out using a multi-modal approach: direct physical examinations for inpatients, telemedicine consultations for outpatients, and referrals to the dermatology clinic for specialized evaluations when necessary.

The telemedicine consultations allowed for remote but thorough assessments, ensuring that even patients unable to visit the hospital due to isolation measures or mobility issues were still evaluated. During these virtual consultations, patients were guided to provide detailed descriptions of their symptoms, supplemented by photographs and video calls when needed, enabling clinicians to accurately document and assess dermatological manifestations.

Skin manifestations were recorded meticulously, noting their onset, location, type (e.g., rash, vesicles, urticaria), progression, and associated symptoms such as pruritus or pain. This data was securely stored in an encrypted database, ensuring the confidentiality and integrity of patient records throughout the study.

This comprehensive approach allowed for a robust analysis of dermatological symptoms across different stages of COVID-19 and in various clinical settings, offering valuable insights into the spectrum of cutaneous manifestations related to the virus and its treatments.

Dermatological Evaluation

Among the cohort, 13 patients presented with skin manifestations potentially linked to COVID-19. These cases were evaluated in detail by the dermatology department, either through direct referral for inpatients or via telemedicine for outpatients. The dermatology team categorized the skin manifestations based on their type (e.g., rash, vesicles, urticaria) and assessed the severity of each case.

The evaluations focused on distinguishing between virus-induced and treatment-related skin reactions, considering the timing of symptom onset and clinical context. The assessment also included documenting the extent of the lesions, symptom severity (e.g., itching, pain), and the necessity for specific dermatological interventions. For complex cases, additional diagnostic tools, such as skin biopsies, were utilized to confirm the underlying cause.

This comprehensive approach ensured that both the nature and severity of dermatological manifestations were accurately captured, allowing for better patient management and care.

Statistical Analysis

Descriptive statistics were used to analyze the data collected in the study. Frequencies and percentages were calculated for categorical variables, such as the types of dermatological manifestations (e.g., maculopapular eruptions, urticaria, vesicular lesions) and their prevalence within the cohort.

In addition to summarizing the skin manifestations, basic descriptive methods were applied to analyze patient demographics (age, sex) and clinical characteristics (e.g., underlying conditions, treatment regimens) to provide insights into any potential patterns or trends. This analysis focused on offering a clear understanding of the distribution and nature of dermatological symptoms in COVID-19 patients without the use of advanced statistical software. Results were organized in tabular form for clarity and ease of interpretation.

RESULTS

This prospective cross-sectional study analyzed 841 patients who visited the COVID-19 outpatient clinic or were hospitalized in the COVID-19 ward at a major university hospital between March 4, 2020, and May 15, 2020. Among these patients, 51.7% (n=435) were male, and 48.3% (n=405) were female, with ages ranging from 9 days to 95 years, and a median age of 52 years. A positive PCR test result for COVID-19 was observed in 31% of the cohort (n=258) (Table 1).

Variables	n	%	
Gender	Female	5	38.5
	Male	8	61.5
	Total number of cases	13	100
Age group (average age 47.4)	30-40 years old	4	30.8
	41-50 years old	3	23.1
	51- 60 years old	5	38.4
	61 and above	1	7.7
	Total number of cases	13	100
PCR	Positive	10	76.9
	Negatif	3	23.1
	Total number of cases	13	100
Computerised tomography	Positive	12	92.3
	Negative	1	7.7
	Total number of cases	13	100
Internal comorbidity	Available	5	38.5
	Not available	8	61.5
	Total number of cases	13	100
Tretment	Hydroxychloroquine	12	37.5
	Oseltamivir	7	21.9
	Azithromycin	10	31.3
	Levocetirizine	2	6.2
	Favipiravir	1	3.1
	Total number of treatments	32	100
ICU/EX	Exitus	1	7.7
	Treatment	12	92.3
	Total number of cases	13	100

PCR: Polymerase chain reaction, ICU: Intensive care unit

The demographic characteristics of the 13 patients who developed skin manifestations related to COVID-19 are

detailed in this table. It provides a comprehensive breakdown by gender, age groups, PCR test results, CT scan findings, and the presence of comorbidities. The information presented highlights the distribution and prevalence of dermatological outcomes in the studied population, offering crucial insights into the clinical implications of COVID-19 across different demographics.

Dermatological Manifestations

Out of the total population, dermatological manifestations were observed in 1.5% of the patients (n=13), with a higher prevalence among males (61.5%, n=8) compared to females (38.5%, n=5). The most commonly affected age group was 51-60 years, accounting for 38.4% of cases (n=5), with a mean age of 47 years. Notably, 76.9% (n=10) of the patients exhibiting skin symptoms tested positive for COVID-19 via PCR, suggesting a strong correlation between the infection and these manifestations. Additionally, 93.3% (n=12) of the patients had CT scans consistent with COVID-19. The majority of patients with dermatological symptoms (61.5%, n=8) did not have any internal comorbidities. Recovery from COVID-19 was achieved in 93.3% (n=12) of the cases, showing a positive prognosis despite the presence of skin symptoms.

Among the COVID-19-related skin manifestations, 50% (n=4) exhibited maculopapular eruptions on the face and trunk. Urticaria was present in 25% of patients (n=2), while purpuric lesions on the lower extremities and erythematous rashes on the face were noted in 12.5% of patients each (n=1). These findings are detailed in Table 2.

Drug-induced Dermatological Reactions

In 0.5% of the cohort (n=5), skin reactions were linked to pharmacological treatments used during the management of COVID-19. These reactions included bullous drug reactions, psoriasisiform eruptions, hypertrichosis, and urticaria. The variability in the onset and severity of these reactions underscored the diverse impact of COVID-19 treatments on dermatological health. This highlights the importance of monitoring and adjusting treatment plans for individuals with drug-induced reactions, as outlined in Table 3.

In drug-induced cases, the latency between drug use and the onset of dermatological symptoms ranged from 2 to 14 days. A wide array of COVID-19 treatments, including hydroxychloroquine, azithromycin, and oseltamivir, were implicated in these reactions. Case 11, which involved a severe bullous reaction, resulted in mortality, while the other patients showed favorable outcomes with the cessation or modification of the suspected drugs.

This table outlines the dermatological manifestations observed in patients with confirmed or suspected COVID-19, providing details on the timing of symptom onset in relation to skin manifestations, the duration and location of rashes, underlying comorbidities, and treatments administered. It captures both direct viral effects on the skin as well as potential drug-induced reactions, offering a comprehensive view of the dermatological impact of COVID-19 (MPE: Maculopapular eruption).

Table 2. Dermatological manifestations associated with COVID-19

Case no	Age	Sex	Symptom	Finding	Skin rash	Duration	Localisation	Rash latency	Internal comorbidity	Treatment	ICU/death
Case 1	42	Male	Shortness of breath, inability to taste and smell	PCR+ CT+	Purpuric skin rash	2 days before Symptoms	Lower limb	6-7 days	None	Hydroxychloroquine Azithromycin	None
Case 2	34	Female	Cough, fever, malaise, headache	PCR+ CT+	MPE	3 days after symptoms	Face	12-13 days	None	Hydroxychloroquine Azithromycin	None
Case 3	40	Male	Shortness of breath, chest pain, muscle pain	PCR+ CT+	MPE	5 days after symptoms	Body, Back	7-8 days	None	Hydroxychloroquine Oseltamivir	None
Case 4	30	Female	Fatigue, cough, shortness of breath	PCR+ CT+	Erythematous rash	1 day after symptoms	Face	18 days	None	Hydroxychloroquine Oseltamivir Azithromycin	None
Case 5	53	Male	Cough	PCR- CT+	Urticaria	8 days after symptoms	Radiating from the abdomen to the back, arm and leg	4-5 days	None	Hydroxychloroquine Oseltamivir Azithromycin Levocetirizine	None
Case 6	41	Male	Cough, Fever	PCR+ CT+	MPE	5 days after symptoms	Face	10 days	Asthma	Hydroxychloroquine Oseltamivir Azithromycin	None
Case 7	51	Male	Cough, shortness of breath	PCR+ CT+	MPE	1 day after symptoms	Body, back	4 days	Hypertension, coronary arterial disease	Hydroxychloroquine Oseltamivir Azithromycin Levocetirizine	None
Case 8	56	Female	Fever, cough, myalgia	PCR+ CT+	Urticaria	3 days after symptoms	Lower limb	2 days	Essential thrombocytosis, vitamin D deficiency	Favipiravir	None

ICU: Intensive care unit, PCR: Polymerase chain reaction, CT: Computed tomography, MPE: Maculopapular eruption

Table 3. Drug-induced dermatological reactions in COVID-19 patients

Case no	Age	Sex	Symptom	Finding	Skin rash	Duration	Localisation	Internal comorbidity	Drugs used for comorbidities	Treatment	Suspicious medicine	ICU/death
Case 9	46	Male	Fever, cough	PCR + CT +	Psoriasiform	10 days after drug use	Face and both elbows	None	Topical corticosteroid, Topical Tacrolimus	Hydroxychloroquine Oseltamivir Azitromisin	Hydroxychloroquine	None
Case 10	51	Female	Shortness of breath, cough	PCR - CT -	MPE	5 days after drug use	Starting from the arms and spreading all over the body	None	None	Prophylactic Hydroxychloroquine (family contacts)	Hydroxychloroquine	None
Case 11	73	Male	Cough, shortness of breath	PCR - CT+	Bullous drug reaction	14 days after drug use	Arm, neck, both lower limbs	DM, CRF, HT	Verapamil hydrochloride + Trandolapril, Clopidogrel, Pantoprazole, Nateglinide, Linagliptin and Indapamide	Hydroxychloroquine Azitromisin	Hydroxychloroquine	Exitus
Case 12	60	Female	Cough	PCR + CT +	Urticaria	14 days after drug use	Starting from the lower extremities and spreading to the whole body	Hipotiroid, HT, DM	None	Hydroxychloroquine Oseltamivir Azitromisin	Hydroxychloroquine Oseltamivir	None
Case 13	40	Male	Sore throat, weakness, myalgia	PCR+ CT+	Hypertrichosis	7 days after drug use	Chest anterior wall	None	None	Hydroxychloroquine Azitromisin	Hydroxychloroquine	None

ICU: Intensive care unit, PCR: Polymerase chain reaction, CT: Computed tomography, MPE: Maculopapular eruption, DM: Diabetes mellitus, CRF: Chronic renal failure, HT: Hypertension

This table presents cases of dermatological reactions induced by pharmacological treatments in COVID-19 patients. It provides detailed information on the onset and duration of skin symptoms after drug administration, the locations of these reactions, associated comorbidities, and the medications involved. The table also highlights drugs used to treat both COVID-19 and pre-existing conditions, identifying cases where specific medications were suspected of causing the dermatological reactions. (MPE: Maculopapular eruption,

COVID-19 Associated Dermatological Manifestations

Case 1: A 42-year-old male patient was admitted to our hospital with increased dyspnea and anosmia. He had no known pre-existing conditions or medication use but had a family member previously diagnosed with COVID-19. Two days prior to the onset of respiratory symptoms, the patient developed severe pruritic purpuric lesions in his lower extremities. The lesions subsided within 1-2 days after hospital admission and initiation of treatment. He tested positive for

COVID-19 via nasopharyngeal swab PCR, and bilateral mild ground-glass opacities were more pronounced in the right basal regions of the lungs on CT. The patient received a five-day course of hydroxychloroquine and azithromycin and was discharged after full recovery.

Case 2: A 34-year-old female presented with a one-week history of headache and fatigue compounded by fever and cough. She had no history of travel or contact with COVID-19 positive individuals. Three days after symptom onset and four days before hospital admission, she developed maculopapular eruptions on her face and mucosal areas. The nasopharyngeal swab PCR test for COVID-19 returned positive results, and chest CT showed opacities consistent with COVID-19. She had no known illnesses or medication history. The patient was treated with hydroxychloroquine and azithromycin for five days and discharged in good health. The skin lesions spontaneously regressed a few days after the discharge.

Case 3: A 40-year-old male was hospitalized a week after developing sore throat, widespread myalgia, fatigue, and subsequent chest pain and dyspnea. He had no international travel history or known COVID-19 contacts. Two days before and five days after the onset of respiratory symptoms, he developed maculopapular eruptions across his back, starting from the interscapular area. He was treated with a five-day regimen of hydroxychloroquine and oseltamivir during his hospital stay and fully recovered. The skin lesions resolved spontaneously after discharge.

Case 4: A 30-year-old female physician working in the COVID-19 ward presented with initial symptoms of malaise, chills, and shivering. These symptoms progressed to cough and dyspnea within four days. Notably, one day after the onset of respiratory symptoms, she developed an erythematous rash on her face and neck (Figure 1). This timing suggests a potential dermatological manifestation associated with COVID-19, which appeared subsequent to the primary respiratory symptoms. A nasopharyngeal swab tested positive for COVID-19, and a chest CT revealed peripheral infiltrations consistent with the viral infection. She received treatment with hydroxychloroquine, azithromycin, and oseltamivir for five days without complications and was subsequently discharged. The emergence and progression of the rash were closely monitored as an indicative symptom of systemic involvement in COVID-19, highlighting the importance of comprehensive symptom assessment in affected patients.

Case 5: A 53-year-old male sought medical attention at a COVID-19 clinic because of a persistent cough lasting ten days without fever. He had no history of travel or contact with confirmed COVID-19 patients and no underlying health conditions or medication use. Although his nasopharyngeal swab was negative, chest CT revealed atypical pneumonia with ground-glass opacities. Eight days after symptom onset and two days post-hospitalization, he developed widespread urticarial lesions from the abdomen to the back, arms, and legs (Figure 2). Treatment with hydroxychloroquine, azithromycin, and oseltamivir was initiated, and the skin lesions responded well to levocetirizine during the last three days of his hospital stay. The patient was discharged in good health condition.

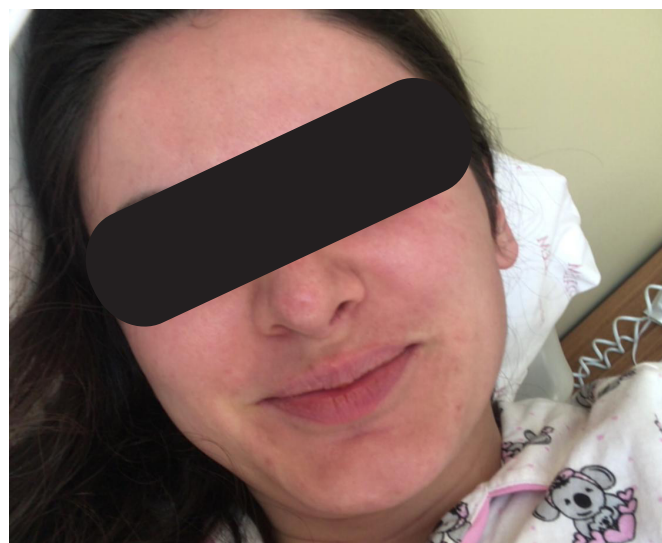

Figure 1. Erythematous rash on face and neck, case 4

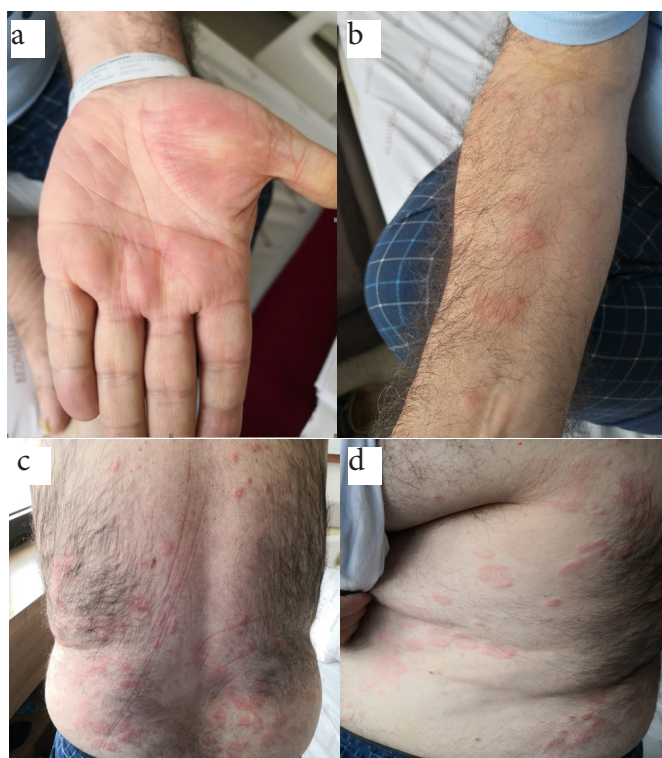


Figure 2. (a, b, c, d): Urticaria associated with COVID-19, case 5

Case 6: A 41-year-old male without any travel history or known contact with COVID-19 patients presented to the COVID clinic with a week-long history of cough and high fever. He had no chronic illnesses or regular medications. Five days after symptom onset and two days before hospital admission, he developed maculopapular eruptions on his face. He tested positive for COVID-19, and chest CT showed minimal bronchiectasis and focal ground-glass opacities in both lung parenchymas consistent with COVID pneumonia. He received hydroxychloroquine, azithromycin, and oseltamivir for five days and was discharged after full recovery. The skin lesions regressed spontaneously within ten days.

Case 7: A 51-year-old male, a specialist doctor working in the COVID ward, presented with sudden onset dyspnea and cough but no fever. The patient's wife was diagnosed

with COVID-19. He had a history of hypertension that was treated with metoprolol, valsartan, and hydrochlorothiazide. In addition, he had a history of irritant contact dermatitis. One day after symptom onset and three days before hospital admission, he developed maculopapular lesions that started on the anterior chest and spread to the back. His nasopharyngeal swab tested positive for COVID-19, and chest CT revealed bilateral faint ground-glass opacities. The patient was treated with hydroxychloroquine, azithromycin, and oseltamivir for five days. The skin lesions responded to levocetirizine during hospitalization and regressed within three days. The patient was discharged in a good condition.

Case 8: 56-year-old female with no history of travel presented with fever, cough, and myalgia. Her SARS-CoV-19 test was positive, and chest CT showed subpleural ground-glass opacities in the right AC lower lobe latero/antero basal segment consistent with COVID pneumonia. Three days after diagnosis and admission, she developed pruritic erythematous plaque lesions on both lower extremities (Figure 3). These skin findings are consistent with those of COVID-associated urticaria. She had no history of urticaria. Laboratory tests showed elevated D-dimer, LDH, and CRP/procalcitonin levels, with normal WBC and other hematological parameters. She was treated with favipiravir and antihistamines, which improved the skin lesions. She was discharged five days later without complications.

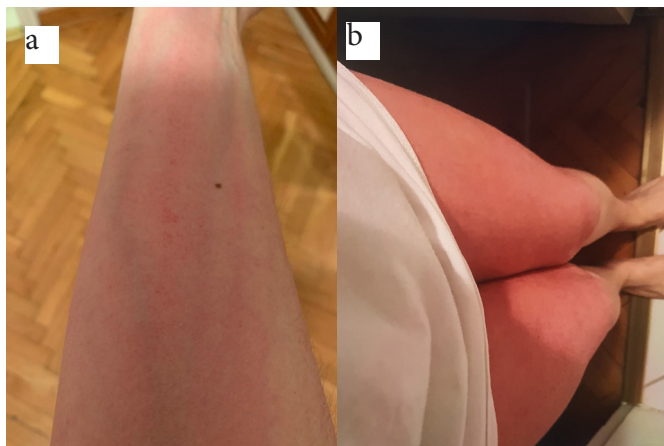


Figure 3. (a, b): Urticaria associated with COVID-19, case 8

Dermatological Manifestations Associated with Pharmacotherapy for COVID-19

Case 9: A 46-year-old male presented with fever and cough at our COVID clinic without any travel history or contact with COVID-19 positive individuals. He had a five-year history of vitiligo for which he was receiving topical corticosteroids and tacrolimus. A nasopharyngeal swab PCR test for SARS-CoV showed positive results. Chest CT showed centrilobular emphysema in the upper lobes of both lungs and thin-walled air cysts, consistent with COVID-19 pneumonia. He received a five-day regimen of hydroxychloroquine, oseltamivir, and azithromycin without complications. Five days post-discharge, the patient returned with erythematous squamous psoriatic eruptions on the face and both elbows, which were attributed to hydroxychloroquine (Figure 4). No new medications have recently been introduced.

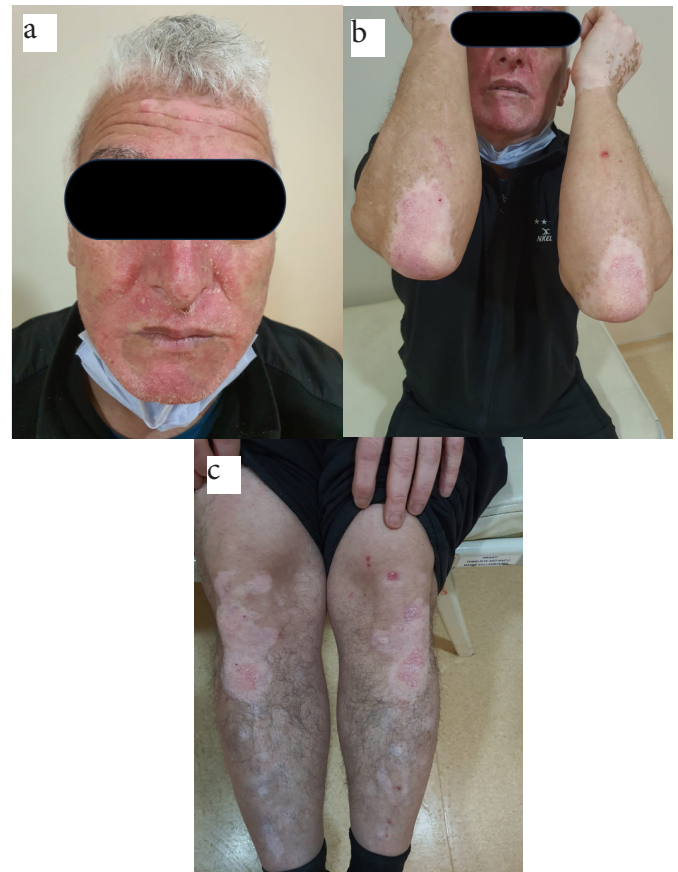

Figure 4. (a, b, c): Psoriasis induced by Hydroxychloroquine, case 9

Case 10: A 51-year-old woman presented with her husband to an external center COVID clinic with dyspnea and cough, and no travel history. The patient's husband was diagnosed with COVID-19. She had no history of systemic or dermatological diseases. The nasopharyngeal SARS-CoV swab test result was negative, and CT scans were normal. Due to suspicion, she was given a five-day course of oral systemic hydroxychloroquine. Five days after completing hydroxychloroquine treatment, the patient developed a widespread maculopapular rash starting from the arms, accompanied by severe itching (Figure 5). Laboratory evaluations revealed eosinophilia (7.13%), Total IgE levels (8.9 kU/L), and eosinophil cationic protein levels (86.5 µg/L). She had not taken any other medications recently and had no history of drug-related dermatological reactions. The patient was treated with a betamethasone dipropionate cream-vaseline mixture, a topical emollient used to soothe and protect the skin, and bilastine, an antihistamine for symptom relief.

Case 11: A 73-year-old male with symptoms of cough and dyspnea presented to our pandemic clinic with cough and dyspnea. He had no fever or travel history, and no family members were diagnosed with COVID-19. He had a history of diabetes, chronic kidney disease, and hypertension and was taking multiple medications including verapamil hydrochloride, trandolapril, clopidogrel, pantoprazole, nateglinide, linagliptin, and indapamide. His nasopharyngeal swab was negative, but chest CT showed ground-glass opacities in both lower lobes. The patient was admitted to the hospital with a preliminary diagnosis of COVID-19. Blood tests revealed elevated D-dimer, LDH, and CRP/procalcitonin

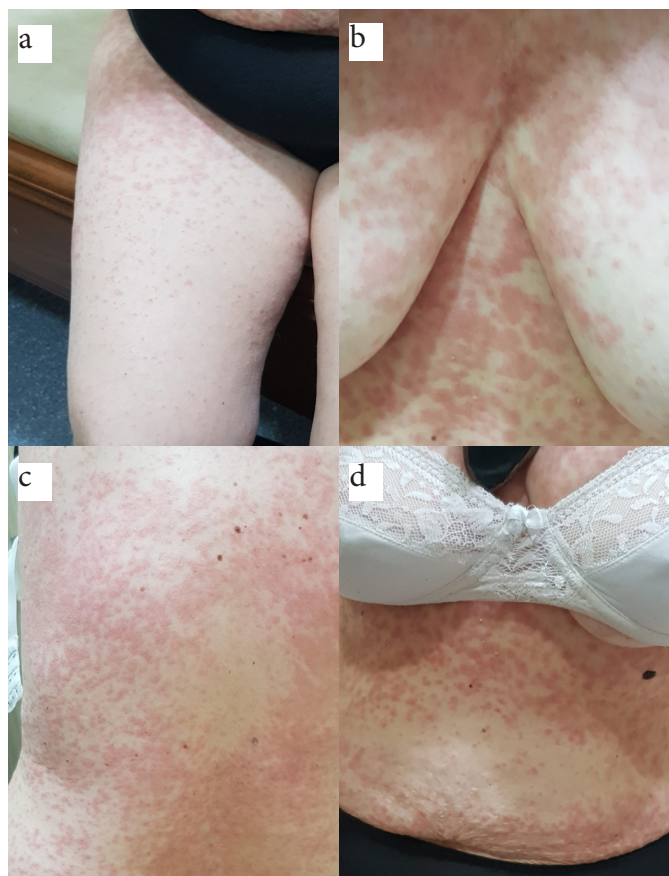

Figure 5. (a, b, c, d): Drug-induced maculopapular rash, case 10

levels. He received a five-day course of hydroxychloroquine and azithromycin and was discharged without complications. Ten days after discharge, he developed bullous drug reactions in his arms, neck, and both lower extremities, which regressed with the application of dermovate cream (Figure 6).

Case 12: A 60-year-old woman presented with a cough at our pandemic clinic. She had no fever or recent travel history of COVID-19. She had hypothyroidism and hypertension but could not recall the names of her medications and reported no recent changes in medication. She underwent nasopharyngeal swabbing and chest computed tomography (CT), which confirmed COVID-19 with ground-glass opacities. The patient was admitted and treated with hydroxychloroquine, azithromycin, and oseltamivir. After a five-day hospital stay without complications. Ten days later, she presented with extensive urticarial plaques, starting from the lower extremities and spreading across the body, which were treated with levocetirizine.

Case 13: A 40-year-old male presented to our pandemic clinic with a sore throat, fatigue, and chills. He had no travel history, although his daughter was COVID-19 positive. The patient had no known systemic diseases or related medications. His nasopharyngeal SARS-CoV PCR test result was positive, and chest CT showed focal ground-glass opacity in the left lower lobe, consistent with COVID-19 pneumonia. He was admitted and treated with hydroxychloroquine and azithromycin for five days. The patient was discharged in good health; however, an increase in hair growth on the chest, arms, and face was observed, which was suspected to be related to hydroxychloroquine use.

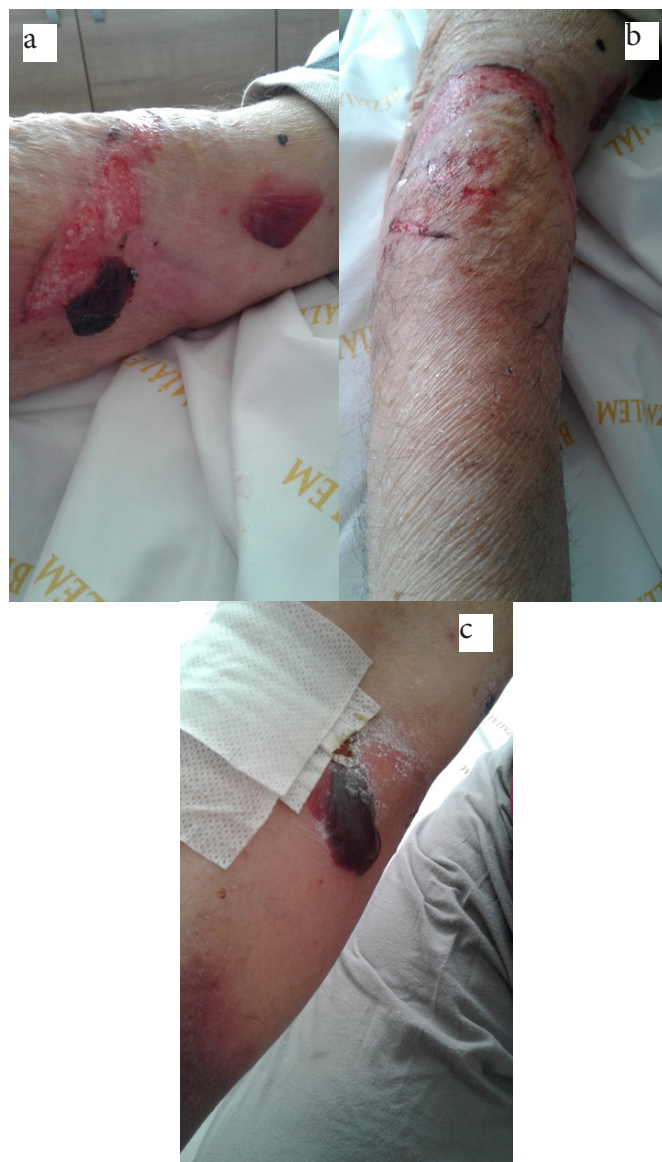

Figure 6. (a, b, c): Bullous drug reaction, case 11

DISCUSSION

The emergence of COVID-19 has expanded our understanding of the impact of the virus on the human body, extending beyond respiratory symptoms to include significant dermatological manifestations. Research has shown that SARS-CoV-2 directly induces a range of skin changes, from the now well-characterized “COVID toes” to more severe entities such as vasculitis, largely owing to the effects of the virus on endothelial cells and small vessel vasculopathy.⁵ Similarly, our study found that 1% of the patients (n=8) developed dermatological manifestations, which aligns with data from similar studies conducted in Europe and Asia, where the reported incidence varies from 0.2% to 20%.⁶ Additionally, the systemic immunological response to the virus, marked by a cytokine storm, involves elevated levels of cytokines, such as interleukin-6 (IL-6) and tumor necrosis factor-alpha (TNF- α). These cytokines can exacerbate or initiate inflammatory skin conditions such as psoriasis or urticaria, even in individuals without a history of these conditions.⁷ In our study, drug-induced dermatological reactions were observed in 0.5% (n=5) of patients, presenting conditions such as bullous

drug reactions, psoriasiform drug eruptions, hypertrichosis, and urticaria. This prevalence reflects findings from global research which underscores the diverse cutaneous adverse reactions associated with COVID-19 treatments. Atzori et al.⁸ have documented severe cutaneous adverse reactions, including Stevens-Johnson syndrome, particularly associated with the use of antimalarials like hydroxychloroquine and antivirals such as oseltamivir. Furthermore, Nobari et al.⁹ provided a systematic review of mucocutaneous reactions, highlighting the wide range of dermatological responses to various COVID-19 pharmacotherapies. Kalikyan¹⁰ also contributes to this body of knowledge by detailing case reports of antibiotics causing hypersensitivity reactions during the pandemic using Naranjo's algorithm to assess causality. Collectively, these studies emphasize the critical need for vigilant monitoring and management of dermatological reactions, advocating for a tailored approach to pharmacotherapy in COVID-19 patients to mitigate these adverse effects. Furthermore, immune dysregulation associated with COVID-19 has been implicated in the reactivation of latent viral infections such as herpes zoster, which may present new or exacerbate existing dermatological conditions during or after the infection.¹⁰ Chilblain-like lesions associated with COVID-19 are considered indicators of a good prognosis in mild cases, whereas vasculopathy-related skin manifestations such as livedo racemosa, retiform purpura, and dry gangrene are linked to more severe disease and poor prognosis.¹¹ The emergence of COVID-19 has necessitated a critical reassessment of therapeutic strategies, not only in terms of virological efficacy, but also in managing the wide array of adverse effects, particularly dermatological manifestations. The complex relationship between COVID-19 pharmacotherapy and skin reactions has gained considerable attention due to its implications for patient safety and adherence to treatment.¹² As with COVID-19 itself, mRNA vaccines developed against the virus have also been observed to induce dermatological manifestations such as type I and IV hypersensitivity reactions, the triggering of autoimmune diseases (bullous pemphigoid, vasculitis), and herpes zoster reactivation. Although the precise mechanisms underlying these cutaneous effects remain unclear, it is hypothesized that mRNA vaccines may bind to ACE2 receptors in the skin, potentially triggering these reactions, with immune responses such as cytokine storms and elevated IL-6 levels contributing to their pathogenesis.¹³ In an international registry analysis of COVID-19 patients with skin manifestations, it was found that while urticarial and morbilliform rashes were short-lived, conditions like pernio and papulosquamous eruptions persisted for longer durations. Some patients, classified as "long-haulers," experienced symptoms lasting over 60 days, indicating a prolonged inflammatory response. These findings underscore the importance of long-term monitoring for dermatological effects in COVID-19 patients.¹⁴ Pharmacotherapy for COVID-19 includes a range of agents, such as antivirals, antimalarials, and antibiotics, each associated with specific dermatological adverse effects. Antimalarials, notably hydroxychloroquine, have been widely

reported to induce cutaneous reactions ranging from mild to severe life-threatening conditions such as Stevens-Johnson syndrome.¹⁵ In line with this, our study found that a significant proportion of patients with skin manifestations (76.9%, n=10) tested positive for COVID-19 by PCR, emphasizing the need for careful monitoring and management of these reactions. Similarly, the use of antivirals such as oseltamivir has been linked to skin rashes and other hypersensitivity reactions, which can significantly affect patient comfort and compliance. Treatment of COVID-19 with various pharmacological agents has been observed to induce a range of cutaneous reactions, which can significantly impact patient management and outcomes. As observed in the clinical classification proposed by Fontes and Rostey (2023), adverse drug reactions (ADRs) from COVID-19 treatments accounted for a considerable proportion of dermatological presentations during the pandemic, underscoring the importance of careful drug selection and monitoring.¹⁶ Emerging studies have proposed various mechanisms by which COVID-19 treatment triggers skin manifestations. The immunomodulatory effects of these drugs, particularly those involving the modulation of cytokine production or inhibition of specific immune pathways, are suspected to underlie many adverse dermatological outcomes. This aligns with our findings, where treatment regimens included hydroxychloroquine, oseltamivir, and azithromycin, which are known for their potential to cause dermatological reactions, particularly in patients with complex medical histories or those exhibiting severe COVID-19 symptoms. This immunological disruption can precipitate or exacerbate conditions, such as eczema, psoriasis, and urticaria, creating a challenging scenario for managing patients who may already have pre-existing dermatological conditions.¹⁷ Dermatologists and clinicians must continuously monitor skin reactions in COVID-19 patients, particularly those on complex medication regimens. Pharmacotherapy should be tailored not just by substituting drugs, but by thoroughly considering the patient's history, the severity of symptoms, and potential drug interactions. Updating treatment guidelines dynamically to incorporate new research findings is crucial. As novel therapeutic agents and vaccines emerge, the dermatology community must swiftly identify and manage new skin manifestations.¹⁸ Recent outbreaks, such as monkeypox, also present unique dermatological challenges that parallel those observed in COVID-19. While COVID-19 is associated with a variety of skin manifestations, monkeypox typically presents with more severe pustular and vesicular rashes.¹⁹ The lessons learned from the COVID-19 pandemic underscore the importance of dermatological vigilance and tailored pharmacotherapy in managing emerging infectious diseases. This awareness is crucial as we continue to develop strategies against current and future outbreaks, ensuring that treatment guidelines remain dynamic and inclusive of new clinical insights.

CONCLUSION

The observed link between COVID-19 and diverse dermatological manifestations underscores the necessity to incorporate dermatological assessments into routine patient

management. Recognizing and addressing skin manifestations directly associated with the virus, such as rashes and other skin changes, are crucial for comprehensive patient care. As we continue to navigate this pandemic, adapting clinical guidelines to include these dermatological insights will enhance treatment efficacy and improve our understanding of COVID-19's extensive systemic effects. Effective management of these skin symptoms, alongside pharmacological side effects, can significantly improve patient outcomes.

ETHICAL DECLARATIONS

Ethics Committee Approval

The study was carried out with the permission of the Bezmialem Vakif University Ethics Committee (Date: 01.072024, Decision No: 155793).

Informed Consent

All patients signed and free and informed consent form.

Referee Evaluation Process

Externally peer-reviewed.

Conflict of Interest Statement

The authors have no conflicts of interest to declare.

Financial Disclosure

The authors declared that this study has received no financial support.

Author Contributions

All of the authors declare that they have all participated in the design, execution, and analysis of the paper, and that they have approved the final version.

REFERENCES

- Marzano AV, Cassano N, Genovese G, Moltrasio C, Vena GA. Cutaneous manifestations in patients with COVID-19: a preliminary review of an emerging issue. *Br J Dermatol*. 2020;183(3):431-442. doi:10.1111/bjd.19264
- Genovese G, Moltrasio C, Berti E, Marzano AV. Skin manifestations associated with COVID-19: Current knowledge and future perspectives. *Dermatology*. 2021;237(1):1-12. doi:10.1159/000512932
- Singh H, Kaur H, Singh K, Sen CK. Cutaneous manifestations of COVID-19: A systematic review. *Adv Wound Care*. 2021;10(2):51-80. doi:10.1089/wound.2020.1309
- Sameni F, Hajikhani B, Yaslianifard S, et al. COVID-19 and skin manifestations: An overview of case reports/case series and meta-analysis of prevalence studies. *Front Med*. 2020;7: 573188. doi:10.3389/fmed.2020.573188
- Freeman EE, McMahon DE, Lipoff JB, et al. The spectrum of COVID-19-associated dermatologic manifestations: an international registry of 716 patients from 31 countries. *J Am Acad Dermatol*. 2020;83(4):1118-1129. doi:10.1016/j.jaad.2020.06.1015
- Panda M, Dash S, Behera B, Sil A. Dermatological manifestations associated with COVID-19 infection. *Indian J Dermatol*. 2021; 66(3):237-245. doi:10.4103/ijd.ijd_464_21
- Ring J. COVID-19 and its implications for dermatology and venereology. *J Eur Acad Dermatol Venereol*. 2020;34(5):914. doi:10.1111/jdv.16414
- Atzori L, Cuenca-Barrales C, Montero-Vilchez T, Molina-Leyva A, Arias-Santiago S. Review of adverse cutaneous reactions of pharmacologic interventions for COVID-19: a guide for the dermatologist. *J Am Acad Dermatol*. 2020;83(6):1738-1748. doi:10.1016/j.jaad.2020.08.006
- Najar Nobari N, Seirafianpour F, Mashayekhi F, Goodarzi A. A systematic review on treatment-related mucocutaneous reactions in COVID-19 patients. *Dermatol Ther*. 2021;34(1):e14662. doi:10.1111/dth.14662
- Kalikyán ZG. Antibiotics hypersensitivity reactions during COVID-19 pandemic. *Immunol Infekcionnye Bolezni*. 2023; 13(3):586-590. doi:10.15789/2220-7619-AHR-8062
- Suchonwanit P, Leerunyakul K, Kositkuljorn C. Diagnostic and prognostic values of cutaneous manifestations in COVID-19. *Dermatol Ther*. 2020;33(4):e13650. doi:10.1111/dth.13650
- Bassetti M, Massone C, Vena A, et al. Skin manifestations in patients with coronavirus disease 2019. *Curr Opin Infect Dis*. 2022;35(2):88-94. doi:10.1097/QCO.0000000000000816
- Nakashima C, Kato M, Otsuka A. Cutaneous manifestations of COVID-19 and COVID-19 vaccination. *J Dermatol*. 2023;50(3): 280-289. doi:10.1111/1346-8138.16651
- McMahon DE, Gallman AE, Hruza GJ, et al. Long COVID in the skin: a registry analysis of COVID-19 dermatological duration. *Lancet*. 2021;21(3):313-314. doi:10.1016/S1473-3099(20)30986-5
- Litaiem N, Hajlaoui K, Karray M, Slouma M, Zeglaoui F. Acute generalized exanthematous pustulosis after COVID-19 treatment with hydroxychloroquine. *Dermatol Ther*. 2020;33(4):e13565. doi:10.1111/dth.13565
- Rostey R, Fontes C. Proposal for clinical classification of cutaneous manifestations in Covid-19 and in post vaccination against Sars-Cov-2: an observational study. *Arch Clin Infect Dis*. 2023. doi:10.5812/archcid-137498
- Gelincik A, Brockow K, Celik G, et al. Diagnosis and management of the drug hypersensitivity reactions in Coronavirus disease 19: an EAACI Position Paper. *Allergy*. 2020;75:2775-2793. doi:10.1111/all.14439
- Niebel D, Novak N, Wilhelmi J, et al. Cutaneous adverse reactions to COVID-19 vaccines: insights from an immuno dermatological perspective. *Vaccines (Basel)*. 2021;9(9):944. doi:10.3390/vaccines9090944
- Prasad S, Galvan Casas C, Strahan AG, et al. A dermatologic assessment of 101 mpox (monkeypox) cases from 13 countries during the 2022 outbreak: skin lesion morphology, clinical course, and scarring. *J Am Acad Dermatol*. 2023;88(5): 1066-1073. doi:10.1016/j.jaad.2022.12.035