

# Effects of repeated anti-VEGF injections on macular vessel density in Turkish proliferative diabetic retinopathy cases

 Ayhan Önal

Department of Ophthalmology, Faculty of Medicine, İstanbul Yeni Yüzyıl University, İstanbul, Türkiye

**Cite this article as:** Önal A. Effects of repeated anti-VEGF injections on macular vessel density in Turkish proliferative diabetic retinopathy cases. *J Health Sci Med.* 2024;7(6):696-702.

Received: 11.09.2024

Accepted: 22.10.2024

Published: 27.10.2024

## ABSTRACT

**Aims:** Although a dramatic increase has been observed in Turkish diabetic retinopathy (DR) patients due to the rising cases of diabetes mellitus (DM), ophthalmological advancements facilitate treatment for DM and its ophthalmic complications, such as proliferative diabetic retinopathy (PDR). To determine the effectiveness of the repeated anti-vascular endothelial growth factor (anti-VEGF) intra-vitreous injections (IVI or IVIs) on the macular vascular density (VD) in PDR.

**Methods:** This theme includes methodological research, retrospective validation studies, and multivariate meta-analysis. The data were obtained from the PubMed, Google Scholar, SCOPUS, WoS, and Google Academic Papers between 2004 and 2023. The injections which completed within 6 months, consecutively administered monthly for three times. This editorial involves diabetic cases that were previously injected with any of Anti-VEGF agent, particularly aflibercept, ranibizumab, and bevacizumab in PDR populace. They were selected over eighteen years who owned high-quality images of “optical coherence tomography angiography” (OCTA). The retinas of thirty-five sufferers from DR were bilaterally analyzed by utilizing keywords.

**Results:** The analysis of VD relevant to PDR did not identify notable alterations of TCP, DCP and SCP, central retinal vascular layers, both before and after the first anti-VEGF IVI cure. Similar events were detected by the consecutive second and third phases. Besides, central retinal thickness (CRT) decreased at least 10 % from the associated with control cases. Twenty eyes were cure-resistant, whereas fifteen eyes were medical care-responsive. Thirty-five humans with PDR were selected. The gender distribution in the study was sixty percent men and forty percent women, and their average age ranged between forty and eighty.

**Conclusion:** The article revealed that VD measures did not illustrate any expressive difference in TCP, DCP and SCP before and after three injections. In other words, the baseline VD measurements did not suggestively conclude while CRT was reducing slightly.

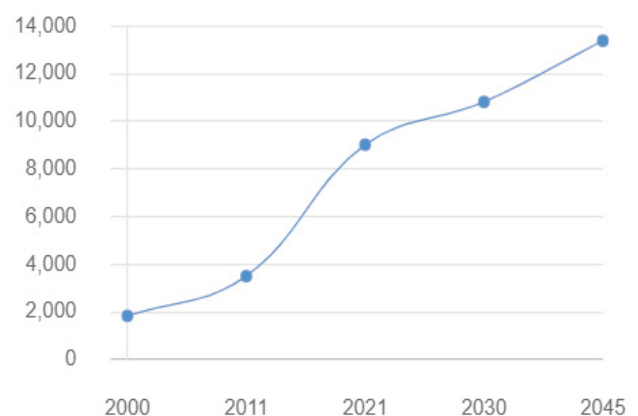
**Keywords:** Anti-VEGF and PDR vessel density, intra-vitreous anti-VEGF and VD in PDR, anti-VEGF and macular VD in PDR, proliferative diabetic retinopathy and anti-VEGF, vascular macular modifications with anti-VEGF in PDR

## INTRODUCTION

An expeditious advancement in health-related problems has been announced in the past few years. This raise has urged eye care professionals to find remedies that might help to cope with the proliferative diabetic retinopathy (PDR)-affected issues.<sup>1,2</sup> As in other countries, diabetic cases have seen an increment in Türkiye for the past few decades. According to the International Diabetes Federation, in 2000, there were almost 1.8 million sufferers from diabetes mellitus (DM) between 20 and 79 years. Then, their numbers reached to nearly nine million in 2021. [Figure 1](#) demonstrates the unusual increase peak of DM population in Türkiye. It similarly reveals the future statistics of the Turkish populace as regards DM might be increased to 13.5 million.<sup>3</sup>

As the image established the prediction speed of diabetic cases in Türkiye, the DR occurrences have been simultaneously rising. This is why the document was focused on considering the repeated anti-vascular endothelial growth factor (anti-VEGF) intra-vitreous injection (IVI) effects in PDR.

## People with diabetes, in 1,000s



**Figure 1.** Diabetes statistics of Türkiye between 2000 and 2045. It is predicted that DM cases will increase by 700 percent in Türkiye between 2000 and 2045.<sup>3</sup>

DM: Diabetes mellitus

**Corresponding Author:** Ayhan Önal, drayhanonal@yahoo.com



This work is licensed under a Creative Commons Attribution 4.0 International License.

The percentage of men with diabetes is 9.12% and in women is 13.10%. The studies declared that Turkish women own a more significant predisposition to DM than men, for instance, this gender affinity is also valid for PDR.<sup>4</sup> If DM is not treated in time; it will seriously predispose heart, kidney, and ocular destructions, such as PDR pattern.<sup>5</sup> It has been remarked that diabetic patients are more likely to develop ophthalmic complications. The commonplace diabetic pathologies based on detractive visual acuity consist of cataracts, macular edema, DR, and glaucoma.<sup>6</sup> Conforming to recent statistics, the percentage of sick people was 13.5%, out of which 6.2% of them were complicated by DR in Türkiye.<sup>3,7</sup>

DR is one of the most frequent reasons for decreased visual acuity belonging to DM, which is accompanied by the high blood glucose level. Retinal signals communicated with brain were blocked that often result in vision loss due to the retinal vascular obstruction in the presence of PDR.<sup>8,9</sup> Different methods and medical techniques are employed to provide PDR remediation. These therapies involve therapeutical solutions, such as corticosteroids, anti-VEGF IVI agents and different sub-units of laser procedure can prevent the leakage in the retinal blood vessels,<sup>10</sup> and one of the extremely effective remedies of DR is the utilization of them.<sup>11</sup> In addition, the injection, which contained anti-bodies, is applied into vitreous and helps to terminate the leakage, and growth of blood vessels by suppressing the VEGF.<sup>12</sup> They chemically named bevacizumab, ranibizumab, and aflibercept, are well-known and commonplace therapeutics in Türkiye.

DR is the most common microvascular complication of Diabetes Mellitus.<sup>13</sup> Nearly one-third of rehabilitants with diabetes develop DR cases worldwide, with a higher risk occurring in the moderate-severe period of the disease.<sup>14</sup> The World Health Organization (WHO) has estimated that DR causes 15-17% of total sight loss in Europe and the USA.<sup>15</sup> The severity condition of vascular lesions has been employed to define and evaluate DR progression, since the detection of retinal inner vascularization became easier. DR is divided into two phases: non-proliferative DR (NPDR), and more destructive form proliferative DR (PDR). These stages are based on the stage of microvascular degradation and concerned with ischemic damage. The development of DR is accompanied by the permeability of the blood-retinal barrier (BRB), growing microvascular complications with vascular endothelial cell. Then, capillary blockage, swelling of the vascular basement membrane (BM), and destructive retinal neuronal and glial irregularities pursue.<sup>16</sup>

Anti-VEGF treatment is the best ophthalmic medication for PDR. The Diabetic Retinopathy Clinical Research Network, known as the DRCR Retina Network, has significantly managed the clinical handling of diabetic eye conditions over the last 2 decades. The network studies guided how to conduct them as an efficient alternative to pan-retinal photocoagulation in eyes suffering from PDR.<sup>17</sup> Medication blocks VEGF when it is intra-vitreally administered to the eye. In general, the procedure is implemented in a treating room or operating theater. After mydriatic eye drop and local anesthetic agent, the peri-orbital skin is cleaned, the ocular surface is sterilized, the orbit is draped, and a clean lid

speculum is inserted before the IVI technique. The solution should be safely injected through the lateral spot, where is 3.5-4 mm far from the limbus, and into the pars plana infero-temporally applied.<sup>18</sup>

The injection process has been performed once-a-month as long as a quarter of year is sufficient period for the loading dosage, more subsequently has followed by regular monthly evaluations for two years in PDR. Each visit consists of a normal retinal examination assessment. The administered cure depends on how severe the condition is and its revision if necessary.<sup>19</sup> The advancement of Anti-VEGF remedy might be an effective tool in the battle against DR-affected visual impairment.<sup>20</sup> The cost of these repetitions-required drugs and the need for a couple of medical visits are an enormity in the ophthalmological sector and induce tremendous concerns regarding the disadvantaged individuals. Nevertheless, this medical procedure provided a clearly superior to the other courses in terms of effectiveness and safety by illustrating a decline in the prevalence of blindness related to PDR.<sup>21</sup>

Anti-VEGF therapy has been illustrated in investigations to contribute to DR decrease in both NPDR and PDR. They can ameliorate the severity of PDR.<sup>22</sup> Therapies for DR with Anti-VEGF involve few limitations; individuals complain by overpriced medicine, the rehabilitation ought not to be discontinued in just a few ophthalmological monitoring and the cure does not own permanently beneficial effects.<sup>23</sup> The medication is not able to be safely discontinued after any known management periods. In agreement with the studies, DR will recur or decline, if the medicine is discontinued,<sup>24</sup> the requirement for regular evaluations and the unpredictability of long-term consequences with them become more complicated and worrisome issues in young PDR individuals.

Anti-VEGF medication, which reduces the mass of DR, is linked to a decrease in the incidence of PDR development. It should be utilized in rehabilitants only who can be regularly monitored if there is retinal edema. On the contrary, it could be implemented to treat the deeper reason of retinopathy connected with PDR and may postpone but does not eliminate a requirement for surgery. Additionally, it is able to occur the tractional retinal detachment, which impairs vision in the presence of progressive vitreoretinal membranes condition.<sup>25</sup>

## METHODS

This report involves methodological research, retrospective validation studies, and multivariate meta-analysis. The data were provided with the PubMed (The National Center for Biotechnology Information, the U.S.), Google Scholar (The Google Co., the U.S.), SCOPUS (The ELSEVIER Co., The Netherlands), WoS (The Clarivate analytics Co., UK & USA), and Google Academic Papers (The Google Co., the U.S.) in between 2004 and 2023. It was prepared in accordance with the principles of the Declaration of Helsinki. The academic work was approved and obtained on 14<sup>th</sup> September 2023 with 774 protocol number by the Medipol University Non-interventional Clinical Researches Ethics Committee (Date: 21.09.2023, Decision No: 5985). All procedures were carried out in accordance with the ethical rules and the principles

of the Declaration of Helsinki. Among PDR events over 18 years receiving anti-VEGF IVI, those with optical coherence tomography angiography (OCTA) images were preferred. The medical records were reviewed to compile baseline demographic data, including gender, diabetes duration, systemic and ocular history, such as IVI procedure. The best-corrected visual acuity (BCVA) of the most recent ophthalmic examination, slit-lamp bio-microscopy, and fundus examination outcomes were noted. The retinas of thirty-five patients with PDR were bilaterally evaluated to deal with this dissertation.

SPSS software (version 25; SPSS, Inc., Chicago, IL, USA) was utilized for statistical analysis. Multivariate analysis aimed at examining the type of prior Anti-VEGF therapy and its effect on variation in VD measurements. The “t” test was applied to evaluate baseline VD in the responsive and treatment-resistant PDR population. Repeated measures and paired “t” quantitative data were managed with ANOVA analytic test. Before and after the first injection, PDR response and VD mass values were compared applying binomial logistic regression and linear regression analysis, respectively, and a “p value” of 0.05 or less was considered graphical.

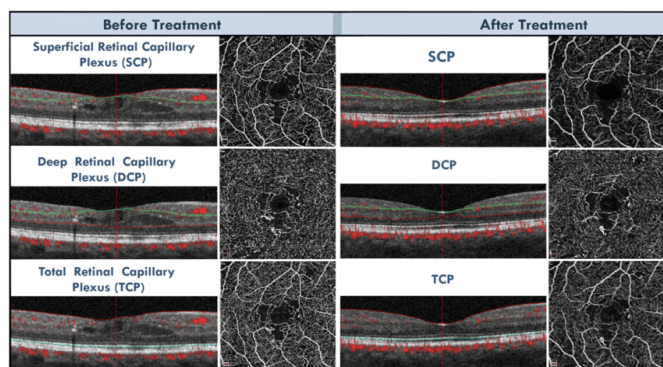
**Exclusion Criteria**

- Exclusion criteria consisted of myopia higher than four diopters, complicated ocular conditions, uncontrolled glaucoma, a history of endophthalmitis, vitreomacular traction, pan-retinal photocoagulation (PRP) laser procedure applied within the last three months, steroidal IVI, and any ocular surgery in the previous six months.
- OCTA images quality-degrading with media opacity were excluded.

**Inclusion Criteria**

- Rehabilitants who had priorly received anti-VEGF IVI were comprised in the paper.
- The RT-Vue XR 100 Avanti device of the Optovue brand (Inc., Fremont, California, USA) was preferred to perform OCTA imaging in eyes with PDR. The best 3 mm and 6 mm photographs were selected because they had a qualified signal-to-noise ratio and were successfully centered on the fovea. images rated 6/10 and above were included.

The automated segmentation of Angio-Vue module was applied to analyze superficial and deep capillary retinal plexus projections. If segmentation troubles were found, Angio-Vue’s proprietary software would be practiced for manual repairing. Due to the deep retinal capillary plexus limits in six eyes and the outside boundary of the superficial capillary plexus in three eyes being incorrectly determined, manual correction was required in nine eyes. The internal limiting membrane (ILM) served as the inner border for the superficial retinal capillary plexus (SCP), and the inner plexiform layer (IPL) functioned as the outer boundary. The inner verge of the deep retinal capillary plexus (DCP) was ten micrometers (µm) inside the IPL, whereas the outside borderline was ten µm below the outer plexiform. This work has informed that segmentation could be difficulty supervised during the presentation of diabetic macular edema (DME) (Figure 2).



**Figure 2.** OCTA images show FAZ and parafoveal vascular network of the macula investigated before and after anti-VEGF treatment in PDR. Following the three intermittent IVIs, micro-decreases were observed in VD belonging to the SCP, DCP, and TCP.<sup>26,27</sup>

OCTA: Optical coherence tomography angiography, FAZ: Foveal avascular zone, anti-VEGF: Anti-vascular endothelial growth factor, PDR: Proliferative diabetic retinopathy, VD: Vessel density, SCP: Superficial retinal capillary, DCP: Deep retinal capillary, TCP: Total retinal capillary plexuses

A quantitative investigation of VD was executed in the OCTA images by virtue of the Angio-Vue program. The software automatically calculated the proportion of the vascular area with flow. It was defined as pixels that possess decorrelation values above the threshold level for the entire ETDRS grid, composed of concentric rings at 1-3-6 mm from the foveal center, and its subunits.<sup>26,27</sup> VD was calculated by applying the entire ETDRS grid, that corresponds to a 3 mm circle in a 3-9-3 mm OCTA and a 6 mm circle in a 6-9-6 mm OCTA scan before and after processing.

**RESULTS**

In the OCTA images, recorded 9 days before and 51 days after the injection, a decrease in macular vessel density was observed due to the effect of two intravitreal anti-VEGF injection cures and was evaluated as significant. Additionally, CRT reduced at least 10.0% from the associated baseline (BL), despite the twenty eyes becoming resistant and fifteen eyes responding to remedy. (126.07±38.02 µm) (p<0.001) were not considered notable following the completion of three Anti-VEGF IVIs (Table 1).

Table 1. VD analysis after first Anti-VEGF injection. <sup>45-47</sup>			
	MD	SD	p
SCP			
Scan=3 9 3 mm			
PDR pt	- 1.37	4.81	0.43
Scan=6 9 6 mm			
PDR pt	- 2.42	5.61	0.25
DCP			
Scan=3 9 3 mm			
PDR pt.	- 42.24	120.67	0.34
Scan=6 9 6 mm			
PDR pt	- 2.35	3.76	0.13
TCP			
Scan=3 9 3 mm			
PDR pt.	0.031	3.02	0.96
Scan=6 9 6 mm			
PDR pt	-3.23	4.96	0.11

MD: Mean difference, pt: Patient, SD: Standard deviation, Table 1 showed the VD volumes had never scientifically changed in TCP, DCP and SCP, before and after the first injection

The scan of 3-9-3 mm within DCP statistically showed an unimportant increase in the VD after the first injection of Anti-VEGF reagent. Likewise, Table 2 demonstrated non-meaningful changes between subgroups of the PDR patients who were injected with second and third anti-VEGF consecutively.

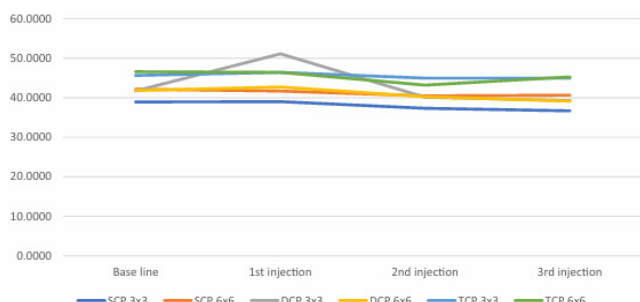
**Table 2. VD analysis after 2<sup>nd</sup> and 3<sup>rd</sup> anti-VEGF injection (inj).**<sup>25-27</sup>

	MD	SD	p
<b>SCP</b>			
<b>Scan=3 9 3 mm</b>			
2 <sup>nd</sup> inj	1.15	4.68	0.18
3 <sup>rd</sup> inj	1.42	4.03	0.07
<b>Scan=6 9 6 mm</b>			
2 <sup>nd</sup> inj	0.44	4.16	0.61
3 <sup>rd</sup> inj	1.03	4.02	0.23
<b>DCP</b>			
<b>Scan=3 9 3 mm</b>			
2 <sup>nd</sup> inj	- 0.03	7.21	0.97
3 <sup>rd</sup> inj	- 0.34	7.06	0.82
<b>Scan=6 9 6 mm</b>			
2 <sup>nd</sup> inj	0.22	5.27	0.82
3 <sup>rd</sup> inj	1.11	4.84	0.26
<b>TCP</b>			
<b>Scan=3 9 3 mm</b>			
2 <sup>nd</sup> inj	0.021	3.48	0.95
3 <sup>rd</sup> inj	- 0.32	4.83	0.73
<b>Scan=6 9 6 mm</b>			
2 <sup>nd</sup> inj	2.17	9.04	0.22
3 <sup>rd</sup> inj	0.71	3.66	0.34

anti-VEGF: Anti-vascular endothelial growth factor, SD: Standard deviation, SCP: Superficial retinal capillary, DCP: Deep retinal capillary, TCP: Total retinal capillary plexuses

Finally, no impressive decrease or increase in VD measurements could be demonstrated with the effect of three consecutive anti-VEGF IVIs. These results are compatible with the outcomes of similar studies in the literature with much larger data.

Figure 3 displays that the VD capacities mathematically remained unchanged via administration of the anti-VEGF IVI. The obtained results were constant in all scans. These outcomes were acquired by three IVI with the associated anti-VEGF for the current theme.



**Figure 3.** Mean VD representation via all anti-VEGF IVIs.<sup>25-27</sup>

VD: Vessel density, anti-VEGF: Anti-vascular endothelial growth factor, IVIs: Intra-vitreous injections

The impact on previous anti-VEGF procedure was observed on the “VD mass changes” after the administration of initial its injection. For this purpose, multivariate analysis was

utilized. Table 3 displayed that both previous medication and the third anti-VEGF IVI did not affect the VD pattern. In addition, it did not act the consequences for DCP, TECP and SCP in both scans.

**Table 3. Multivariate analysis.**<sup>25-27</sup>

	f	p
<b>Effect on treatment of anti-VEGF in VD measurements</b>		
PT	1.106b	0.368
<b>Btw-sub effects of anti-VEGF</b>		
<b>SCP</b>		
Scan=3 9 3 mm	0.575	0.565
Scan=6 9 6 mm	2.358	0.106
<b>DCP</b>		
Scan=3 9 3 mm	0.905	0.413
Scan=6 9 6 mm	0.284	0.756
<b>TCP</b>		
Scan=3 9 3 mm	0.002	0.998
Scan=6 9 6 mm	0.184	0.833
<b>Effect on previous treatment of anti-VEGF in VD measurements</b>		
PT	1.333b	0.265
<b>Btw-sub effects of anti-VEGF's previous treatment</b>		
<b>SCP</b>		
Scan=3 9 3 mm	0.085	0.918
Scan=6 9 6 mm	0.603	0.553
<b>DCP</b>		
Scan=3 9 3 mm	1.716	0.193
Scan=6 9 6 mm	0.008	0.992
<b>TCP</b>		
Scan=3 9 3 mm	0.083	0.921
Scan=6 9 6 mm	0.577	0.566

anti-VEGF: Anti-vascular endothelial growth factor, Btw: Between, sub: Subjects, PT: Pillai's trace, VD: Vessel density, SCP: Superficial retinal capillary, DCP: Deep retinal capillary, TCP: Total retinal capillary plexuses

**Table 4. T-test- difference in VD measurement of treatment-resistant versus responsive groups.**<sup>25-27</sup>

	MD	p
<b>SCP</b>		
Scan=3 9 3 mm	- 0.00378	0.997
Scan=6 9 6 mm	1.22158	0.412
<b>DCP</b>		
Scan=3 9 3 mm	0.14736	0.932
Scan=6 9 6 mm	- 1.70605	0.403
<b>TCP</b>		
Scan=3 9 3 mm	1.02575	0.542
Scan=6 9 6 mm	0.65226	0.728
CRT	- 60.37878	0.014*

SCP: Superficial retinal capillary, DCP: Deep retinal capillary, TCP: Total retinal capillary plexuses

The relationship between the response of PDR to Anti-VEGF and the dimensions of VD was shown in Table 4. According to t test, no remarkable changes were observed in CRT and TCP thicknesses following the injections.

Even though the “binominal logistic regression model” was applied for determining the VD quantifications, the “linear regression model” was considered for the testing of the correlation with the associated PDR therapy. Similar endings were noticed in the t-tests (Table 5).

**Table 5. Correlation between macular edema (ME) response to treatment incorporating Anti-VEGF and VD measurement.<sup>25-27</sup>**

		B	p
VD measurement baseline as predictor to PDR resistant	<b>SCP</b>		
	Scan=3 9 3 mm	0.198	0.172
	Scan=6 9 6 mm	- 0.282	0.062
	<b>DCP</b>		
	Scan=3 9 3 mm	0.045	0.506
	Scan=6 9 6 mm	0.093	0.126
	<b>TCP</b>		
	Scan=3 9 3 mm	- 0.317	0.066
	Scan=6 9 6 mm	0.185	0.102
PDR response to 1 <sup>st</sup> Anti-VEGF injection	<b>SCP</b>		
	Scan=3 9 3 mm	- 2.503	0.212
	Scan=6 9 6 mm	- 2.321	0.195
	<b>DCP</b>		
	Scan=3 9 3 mm	- 0.605	0.802
	Scan=6 9 6 mm	- 2.395	0.295
	<b>TCP</b>		
	Scan=3 9 3 mm	- 1.373	0.401
	Scan=6 9 6 mm	- 1.658	0.406

Table 5 explained that an insignificant VD reduction was formed in PDR-related patients with DME after a single dose of anti-VEGF injection, SCP: Superficial retinal capillary, DCP: Deep retinal capillary, TCP: Total retinal capillary plexuses

## DISCUSSION

The result confirmed the absence of major effect of three consecutive anti-VEGF IVIs on macular VD referred to PDR. It was also clear from the study that VD was not linked to previously performed procedures.

Results that confirm our study or do not support our hypothesis are discussed with a few examples below.

The article of Sorour et al.,<sup>27</sup> “Anti-VEGF IVI effect in macular VD variations and PDR-associated DME” paralleled our outcomes.

Another example is the review by Zhao et al.,<sup>28</sup> they confirmed how VD differs after improvement of PDR with pan-retinal photocoagulation (PRP) or intravitreal conbercept (IVC). Their research compared retinal VD and modifications to OCTA, and they revealed that the method did not improve the PDR-VD process.

Chatziralli et al.<sup>29</sup> detailed their research to evaluate the relationship between retinal nonperfusion and Anti-VEGF

IVI in PDR subjects and they searched the literature to determine whether IVI had effects on the density of the macula and retinal vessels. The results of the paper did not provide any convincing evidence for effective amelioration of the PDR-VD process with Anti-VEGF.

Mirshahi et al.<sup>30</sup> Announced their article regarding macular microvascular changes after intravitreal bevacizumab injection in diabetic macular edema.

Our scientific study, to reduce VD with repeated Anti-VEGF IVIs in PDR, revealed details much the same to those discovered by the researchers above.

While most similar studies are based on the general vascular density of the whole retina, a more specific area, the macula, was preferred for this study. As is known, the normal macula consists of FAZ and perifovea. FAZ is an avascular region responsible for detailed, daytime and color vision. In cases of PDR, pathologies that threaten central vision such as bleeding, DME, abnormal vascular proliferation, and macular hole because of its location in the macula rather than the peripheral retina are observed. The effects of three repeated injections were “much less” than the VD reducing effects stated in the literature might be considered a remarkable difference. Therefore, more careful planning in the application of Anti-VEGF IVI in Turkish PDR patients would provide advantages. In summary, except for selected cases, discontinuation of more than 1 (one) course of anti-VEGF IVI could be considered and discussed in a Turkish ophthalmology council.

## Theoretical Implications

It similarly described the increasing rate of diabetes in Turkiye, which needs to be contemplated. DR approaches and VD responses in the duration of repeated anti-VEGF IVI were discussed. The article aimed at reaching its optimal number of repetition cycle.

## Practical Implications

This composition, which provides an insight into the conduct, will be beneficial for the ophthalmologists to discuss and comment the ideal number of repeated pharmaceuticals, and to inspect the relationship between anti-VEGF IVI and VD modifications in PDR for Turkiye.

## Limitations

Although this article has interesting implications, there are several corresponding shortcomings in the resulting analysis. Anti-VEGF IVI associated with DR was specifically addressed in the review; other parameters that may affect the reliability, results, hypotheses and recommendations of the study should not be forgotten. Some of these are the number of cases, the age of the patient, additional ocular and systemic diseases, and the duration of the study. For example, in this article, the Turkish diabetic population aged Eighteen and over was selected, although the disease was seen at the age of Fourteen. Because local data do not contain sufficient figures regarding the early adolescence period of DM. This article was conducted in the Turkish context only, thus the findings may differ in the other countries. In this thesis, the effects of repeated

doses were checked; The situation may change depending on long-term use. Moreover, the same Anti-VEGF agent was not regularly injected. Any of the Ranibizumab, Bevacizumab or Aflibercept agents, available in Turkish medicine market, was injected. This was also considered as a limiting parameter.

## CONCLUSION

This theme addressed how to consider and accredit the ideal number of repeated anti-VEGF IVIs for the PDR rehabilitation plan. The PDR-VD study indicated that the required improvement in SCP, TCP and DCP and reduction in VD before and after the first Anti-VEGF IVI administration were not achieved. Similar actions were seen in the second and third repeated processes. The findings subsequently confirmed that CRT was almost never lowered in relevant cases, with many eyes not responding to treatment, whereas a few eyes were care-responsive. Literature studies recommend monthly anti-VEGF injections for three times depending on the loading dosage in PDR, and then regular 6-monthly follow-up for the first two years, and eye examinations to determine whether anti-VEGF injections are necessary or not. In this study, mathematically, much lower variations were observed under the influence of the agent in basic VD dimensions than the other studies. Therefore, instead of three-monthly repeated loading doses, a single dose of IVI and then 6-monthly checks in the first 2 years and annual checks after 2 years could be recommended.

For impact and cost planning, anti-VEGF agents that are not available in Türkiye might be produced and/or imported. Efforts to discover new drugs that eliminate macular abnormal VD, such as anti-VEGF and other agents, could be accelerated.

## Future Additional Recommendations

This work is also composed of the recommendations because of further research. Researchers can examine other approaches of DR such as corticosteroids medicines, and several types of laser cure to see whether they are effective to treat the illness or not. Since exposure to DM cases have developed as early as the age 14, the baseline of screening should involve with age for Türkiye, and much more research shall be assisted to see the difference in Turkish reports. Furthermore, the long-term effects of Anti-VEGF IVI need to be conceived.

## ETHICAL DECLARATIONS

### Ethics Committee Approval

The study was carried out with the permission of the Medipol University Non-interventional Clinical Researches Ethics Committee (Date: 21.09.2023, Decision No: 5985).

### Informed Consent

Because the study was designed retrospectively, no written informed consent form was obtained from patients.

### Referee Evaluation Process

Externally peer-reviewed.

## Conflict of Interest Statement

The authors have no conflicts of interest to declare.

## Financial Disclosure

The authors declared that this study has received no financial support.

## Author Contributions

All of the authors declare that they have all participated in the design, execution, and analysis of the paper, and that they have approved the final version.

## REFERENCES

1. Field M, Buccheri A, King O, et al. Rural health service leaders co-design state-wide research addressing an emerging health issue: a case report. *Aust J Rural Health*. 2022;30:884-890.
2. Babes EE, Bustea C, Behl T, et al. Acute coronary syndromes in diabetic patients, outcome, revascularization, and antithrombotic therapy. *Biomed Pharmacotherapy*. 2022;148:112772.
3. IDF Diabetes Atlas 10<sup>th</sup> Edition: Turkey Diabetes report, 2000-2045. Available from: <https://diabetesatlas.org/data/en/country/203/tr.html>. Accessed July 3, 2024.
4. Tosun A S, Gundogdu N A, Tas F, Ates S. Experiences, thoughts, and feelings of patients with a diabetic foot ulcer in Turkey: a qualitative descriptive study. *J Vasc Nurs*. 2022;40:140-147.
5. Thomas M. The clustering of cardiovascular, renal, adipome-metabolic eye and liver disease with type 2 diabetes. *Metabolism*. 2022;128:154961.
6. Kumar Y, Gupta S. Deep transfer learning approaches to predict glaucoma, cataract, choroidal neovascularization, diabetic macular edema, drusen and healthy eyes: an experimental review. *Arch Comp Method Eng*. 2023;30:521-541.
7. Ulgu M, Gulkesen KH, Akunal A, et al. Characteristics of diabetes mellitus patients in Turkey: an analysis of national electronic health records. *Turk J Med Sci*. 2023;53:316-322.
8. Ansari P, Tabasumma N, Snigdha NN, et al. Diabetic retinopathy: an overview on mechanisms, pathophysiology, and pharmacotherapy. *Diabetology*. 2022;3:159-175.
9. Grauslund J. Diabetic retinopathy screening in the emerging era of artificial intelligence. *Diabetologia*. 2022;65:1415-1423.
10. Zehden JA, Mortensen XM, Reddy A, Zhang AY. Systemic and ocular adverse events with intravitreal anti-VEGF therapy used in the treatment of diabetic retinopathy: a review. *Curr Diab Rep*. 2022;22:525-536.
11. Bahr TA, Bakri SJ. Update on the management of diabetic retinopathy: anti-vegf agents for the prevention of complications and progression of nonproliferative and proliferative retinopathy. *Life (Basel)*. 2023;13:1098.
12. Uludag G, Hassan M, Matsumiya W, et al. Efficacy and safety of intravitreal anti-VEGF therapy in diabetic retinopathy: what we have learned and what should we learn further?. *Expert Opin Biol Ther*. 2022;22:1275-1291.
13. Gardner TW, Davila JR. The neurovascular unit and the pathophysiologic basis of diabetic retinopathy. *Graefes Arch Clin Exp Ophthalmol*. 2017;255:1-6.
14. Yau JW, Rogers SL, Kawasaki R, et al. Global prevalence, and major risk factors of diabetic retinopathy. *Diabetes Care*. 2012;35:556-564.
15. Pizzarello L, Abiose A, Ffytche T, et al. Vision 2020: the right to sight: a global initiative to eliminate avoidable blindness. *Arch Ophthalmol*. 2004;122:615-620.

16. Stitt AW, Curtis TM, Chen M, et al. The progress in understanding and treatment of diabetic retinopathy. *Prog Retin Eye Res.* 2016;51:156-86.
17. Sun JK, Jampol LM. the diabetic retinopathy clinical research network (DRCR. net) and its contributions to the treatment of diabetic retinopathy. *Ophthalmic Res.* 2019;62:225-230.
18. Boyle J, Vukicevic M, Koklanis K, Itsiopoulos C. Experiences of patients undergoing anti-VEGF treatment for neovascular age-related macular degeneration: a systematic review. *Psychol Health Med.* 2015;20:296-310.
19. Ghanchi F. The Royal College of Ophthalmologists' clinical guidelines for diabetic retinopathy: a summary. *Eye (Lond).* 2013;27:285-287.
20. Pramanik S, Mondal LK, Paine SK, et al. Efficacy and cost-effectiveness of anti-VEGF for treating diabetic retinopathy in the Indian population. *Clin Ophthalmol.* 2021;3341-3350.
21. Azad R, Chandra P, Gupta R. The economic implications of the use of anti-vascular endothelial growth factor drugs in age-related macular degeneration. *Indian J Ophthalmol.* 2007;55:441.
22. Wells JA, Glassman AR, Ayala AR, et al. Aflibercept, bevacizumab, or ranibizumab for diabetic macular edema. *N Eng J Med.* 2015;372:1193-1203.
23. Blankenship G W. Fifteen-year argon laser and xenon photocoagulation results of Bascom Palmer Eye Institute's patients participating in the diabetic retinopathy study. *Ophthalmology.* 1991;98:125-128.
24. Mirshahi A, Roohipoor R, Lashay A, Mohammadi SF, Abdoallahi A, Faghihi H. Bevacizumab-augmented retinal laser photocoagulation in proliferative diabetic retinopathy: a randomized double-masked clinical trial. *Eur J Ophthalmol.* 2008;18:263-269.
25. Zhao Y & Singh R P. The role of anti-vascular endothelial growth factor (anti-VEGF) in the management of proliferative diabetic retinopathy. *Drugs Context.* 2018;7:212532
26. Aaltonen K, Kujala J. A project lifecycle perspective on stakeholder influence strategies in global projects. *Scandinav J Manag.* 2019; 26:381-397.
27. Sorour OA, Sabrosa AS, Yasin Alibhai A, et al. Optical coherence tomography angiography analysis of macular vessel density before and after anti-VEGF therapy in eyes with diabetic retinopathy. *Int Ophthalmol.* 2019;39:2361-2371.
28. Zhao H, Yu M, Zhou L, Li C, Lu L, Jin C. Comparison of the effect of pan-retinal photocoagulation and intravitreal conbercept treatment on the change of retinal vessel density monitored by optical coherence tomography angiography in patients with proliferative diabetic retinopathy. *J Clin Med.* 2021;10:4484.
29. Chatziralli I, Touhami S, Cicinelli MV, et al. Disentangling the association between retinal non-perfusion and anti-VEGF agents in diabetic retinopathy. *Eye (Lond).* 2022;36:692-703.
30. Mirshahi R, Falavarjani KG, Molaei S, et al. Macular microvascular changes after intravitreal bevacizumab injection in diabetic macular edema. *Canadian J Ophthalmol.* 2021;56:57-65.