

# Osajin is a promising candidate for sepsis-induced brain damage via suppression of the 8-OHdG/Bax/caspase-3 pathway in a rat model of sepsis

✉ Mohammad Alhilal<sup>1</sup>, ✉ Serkan Yıldırım<sup>2</sup>, ✉ Hüseyin Serkan Erol<sup>3</sup>, ✉ Suzan Alhilal<sup>4</sup>,  
✉ Metin Kılıçlıoğlu<sup>2</sup>, ✉ Berrah Gözegir<sup>2</sup>, ✉ Murat Koç<sup>5</sup>, ✉ Mesut Bünyami Halıcı<sup>6</sup>

<sup>1</sup>Department of Nursing, Faculty of Health Sciences, Mardin Artuklu University, Mardin, Türkiye

<sup>2</sup>Department of Pathology, Faculty of Veterinary Medicine, Atatürk University, Erzurum, Türkiye

<sup>3</sup>Department of Biochemistry, Faculty of Veterinary Medicine, Kastamonu University, Kastamonu, Türkiye

<sup>4</sup>Department of Medical Services and Techniques, Vocational School of Health Services, Mardin Artuklu University, Mardin, Türkiye

<sup>5</sup>Department of Tradational, Complementary and Integrative Medicine, Public Health Institute, Ankara Yıldırım Beyazıt University, Ankara, Türkiye

<sup>6</sup>Department of Biochemistry, Faculty of Veterinary Medicine, Atatürk University, Erzurum, Türkiye

**Cite this article as:** Alhilal M, Yıldırım S, Erol HS, et al. Osajin is a promising candidate for sepsis-induced brain damage via suppression of the 8-OHdG/Bax/caspase-3 pathway in a rat model of sepsis. *J Health Sci Med.* 2025;8(2):191-196.

Received: 06.01.2025

Accepted: 24.01.2025

Published: 21.03.2025

## ABSTRACT

**Aims:** We examined the protective effect of the natural product osajin against sepsis-induced brain damage by targeting the 8-hydroxydeoxyguanosine (8-OHdG)/Bcl-2-associated protein (Bax)/caspase-3 pathway in the brain tissue of septic rats.

**Methods:** Osajin was isolated from *Maclura pomifera* fruit, the structure was confirmed, and a rat model of brain damage was established by the cecal ligation and puncture (CLP) method. Osajin was administered to the animals with sepsis-associated brain damage at 150 and 300 mg/kg. Following euthanasia, histopathological examination, detection of 8-OHdG by immunohistochemistry, and the estimation of Bax and caspase-3 expression using an immunofluorescent technique in the brain tissue were performed.

**Results:** Histopathological examination revealed the presence of severe inflammation, marked degeneration, and necrosis in the brains of rats with sepsis. The results of immunohistochemical and immunofluorescent assays revealed that the CLP technique induced marked 8-OHdG, Bax, and caspase-3 expression in the brain tissues of septic rats compared with those in healthy rats. Osajin administration at a dose of 150 mg/kg ( $p < 0.05$ ) and 300 mg/kg ( $p = 0.0022$ ) reversed the histopathological changes and significantly ameliorated the increased 8-OHdG, Bax, and caspase-3 expression compared with that in septic rats.

**Conclusion:** The histopathological, immunohistochemical, and immunofluorescent evidence indicates that osajin can reverse brain damage caused by sepsis by inhibiting the 8-OHdG/Bax/caspase-3 pathway. Accordingly, this natural product represents a promising candidate for the management of brain damage in septic patients.

**Keywords:** Bax, caspase-3, osajin, sepsis, brain damage, 8-OHdGs

## INTRODUCTION

Sepsis is a major problem for intensive care units and results in a high mortality rate worldwide. More than 30 million cases of sepsis and 5 million deaths occur annually.<sup>1</sup> Its management also represents a significant financial burden to the health sector worldwide. Sepsis causes damage to many organs, including the brain, as a result of an exaggerated immune response.<sup>2</sup> Although the molecular mechanisms underlying brain damage associated with sepsis are complex and have been inadequately described, neuronal apoptosis is an important pathophysiological mechanism that drives sepsis-associated brain damage through the activation of inflammation, oxidative stress, and mitochondrial damage mechanisms.<sup>3</sup> Sepsis-associated brain damage results in

many complications, such as blood-brain barrier dysfunction and sepsis-associated encephalopathy, which alters the mental status of septic patients admitted to intensive care units.<sup>4,5</sup> Greater than 70% of sepsis patients develop sepsis-associated encephalopathy (SEA).<sup>6</sup> Currently, there are no specific treatments for sepsis-induced brain dysfunction, although the use of antibiotics and fluid support ameliorates the symptoms.<sup>7</sup> We hypothesize that targeting oxidative stress, mitochondrial damage, and apoptosis mechanisms may be an important strategy for managing brain damage during sepsis and its various complications that lead to consciousness disorders, seizures, and coma. Accordingly, the use of agents that possess antioxidant and antiapoptotic

**Corresponding Author:** Mohammad Alhilal, mohammadalhilal@artuklu.edu.tr



This work is licensed under a Creative Commons Attribution 4.0 International License.

properties shows beneficial results. Osajin is an isoflavone isolated from the *Maclura pomifera* (rafinesque) Schneider fruits that has many therapeutic properties,<sup>8-11</sup> including a protective effect against sepsis-induced multiple organ injury. Our previous studies showed that osajin could reverse liver<sup>12</sup> and kidney<sup>13</sup> damage in a rat model of sepsis induced by cecal ligation and puncture (CLP) by suppressing oxidative stress, inflammation, and apoptosis in various tissues. To date, we have not found any studies of the effects of osajin on sepsis-induced brain damage in rats. Based on our previous data, we aimed to examine the neuroprotective effects of osajin against brain damage resulting from sepsis in a rat model by targeting the 8-hydroxydeoxyguanosine (8-OHdG)/Bcl-2-associated protein (Bax)/caspase-3 pathway, which promotes oxidative DNA damage, mitochondrial damage, and apoptosis. The results were corroborated by a histopathological study of the rat brain tissue.

## METHODS

### Isolation and Characterization of Osajin

The verification of the *Maclura pomifera* species was done using international diagnostic methods. The extraction, isolation, and purification of osajin were carried out by chromatographic methods and confirmation of the chemical structure was done using spectroscopic methods (Figure 1). These steps are explained in detail in previous studies.<sup>12,13</sup>

### Animals, Experimental Groups, and Sepsis Model

The experiment was conducted using 30 adult male Sprague-Dawley rats (weighing 200-250 g). Ethical approval was obtained from the Atatürk University Rectorate Animal Experiments Local Ethics Committee (Date: 01.09.2015, Decision No: 133). All procedures were carried out in accordance with the ethical rules and the principles. The rats were divided equally into five experimental groups as shown in Table and allowed to acclimate for seven days. Polymicrobial sepsis was induced using the CLP method as described in previous studies.<sup>12,13</sup> Briefly, after administering general anesthesia consisting of thiopental sodium, the cecum was withdrawn, tied, and two punctures were made to allow the contents of the cecum to spread into the peritoneal cavity. It was then restored and the abdomen was closed. Complete details regarding the study groups are listed in Table.

The doses of osajin were determined based on previous studies.<sup>11,14</sup> After applying the CLP technique for 24 h, the animals were euthanized under general anesthesia. The brains were immediately collected and placed in a suitable fixative solution for subsequent examination.

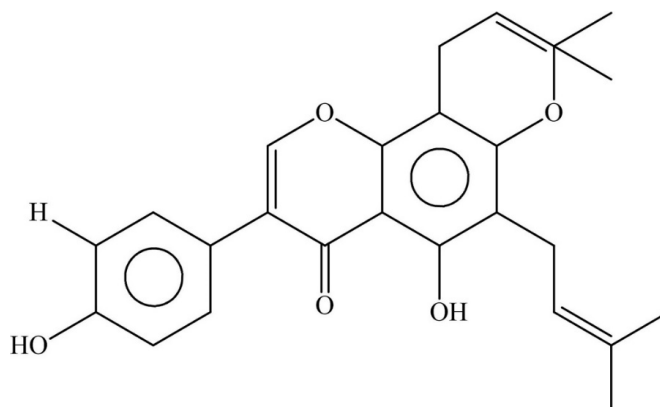


Figure 1. Chemical structure of osajin

### Histopathological Examination of the Brain Tissue

After fixing the brain tissues in 10% neutral formalin solution for 48 h, they were subjected to a consecutive routine series of alcohol and xylol washes. The samples were embedded in paraffin and 4- $\mu$ m thick tissue sections were prepared. The tissue sections were examined using a light microscope (Olympus BX 51, Japan) following hematoxylin-eosin (H&E) staining.

### Immunohistochemical Evaluation of the Brain Tissue

Based on the procedures described previously<sup>13</sup> for immunoperoxidase evaluation, the primary antibody (8-OHdG, no: sc66036) was applied to the tissues and incubated accordingly. The 3-3' diaminobenzidine (DAB) chromogen was used for color development. The stained sections were examined by light microscopy (Zeiss AXIO, Germany).

### Double Immunofluorescence Evaluation of the Brain Tissue

The sample preparation procedures were done as previously described.<sup>13</sup> For immunoperoxidase examination, the primary antibody (Bax, no: sc7480) was applied to the tissues. A secondary antibody was used as a secondary marker (FITC, no: ab6785) and the samples were incubated in the dark for 45 min. The same previous steps were applied to the tissue sections using caspase 3 (no: sc56053) as a second primary antibody and texas red (no: ab6719) as an immunofluorescence secondary antibody. The samples were incubated in the dark for 45 min. DAPI with mounting medium (no: D1306 D) was applied to the sections and incubated for 5 min in the dark before examination of the stained sections under a fluorescence microscope (Zeiss AXIO, Germany).

Table. Details of the experimental groups

Group name	Number of rats	Description	Administration method of osajin or ceftriaxone/time	Brain tissue collection time
Sham	6 rats	Laparotomy without CLP	-	24 hours after the operation
Sepsis	6 rats	CLP	-	24 hours after the CLP technique
Osajin150	6 rats	150 mg/kg (BW) osajin+CLP	Oral gavage/15 minutes before the CLP technique	24 hours after the CLP technique
Osajin300	6 rats	300 mg/kg (BW) osajin+CLP	Oral gavage/15 minutes before the CLP technique	24 hours after the CLP technique
Ceftriaxone	6 rats	50 mg/kg (BW) ceftriaxone+CLP	Intraperitoneal injection/15 minutes before the CLP technique	24 hours after the CLP technique

CLP: Cecal ligation and puncture, BW: Body weight

### Statistical Analysis

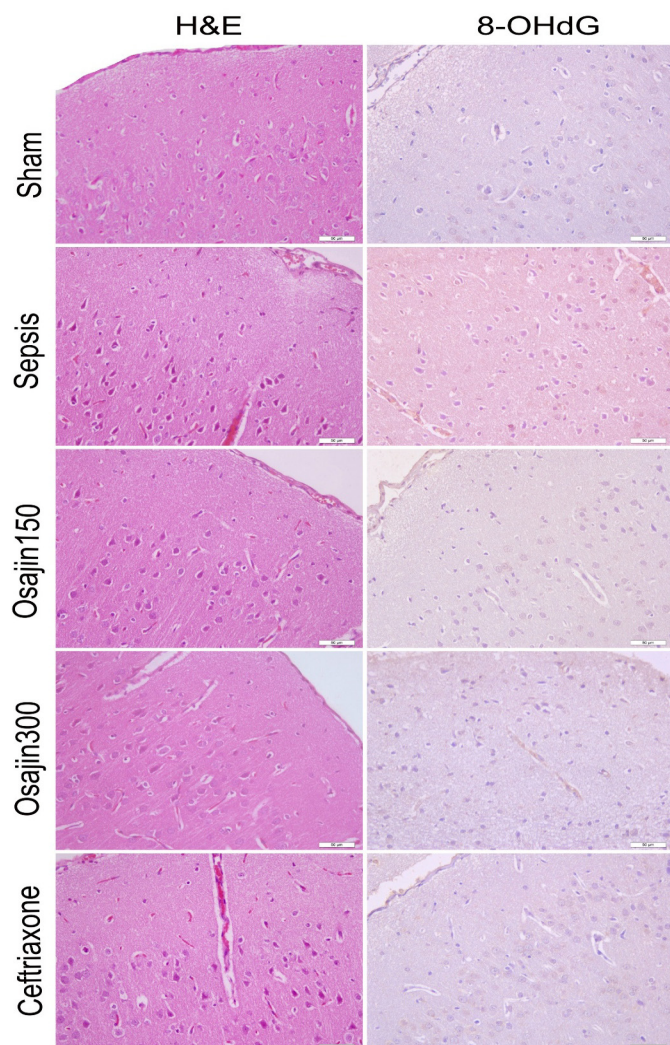
GraphPad prism (version 8.0.2) software was used for statistical analysis of the histopathological assays.  $p < 0.05$  was considered statistically significant. The non-parametric Kruskal-Wallis test was used to detect group interactions and the Mann-Whitney U test was used to determine differences between groups. To determine the intensity of the positive staining from the images obtained by immunohistochemical and immunofluorescence staining, five random areas were selected from each image and evaluated by the ZEISS Zen Imaging Software program. A one-way ANOVA followed by Tukey's test was performed to compare positive immunoreactive cells and immunopositive stained areas with those of healthy controls.  $p < 0.05$  was considered statistically significant and the data are presented as the mean  $\pm$  SD.

## RESULTS

### Histopathological Examination

The brain tissues were examined histopathologically in all experimental groups and the results are summarized as follows:

**Sham group:** Normal histological structures in the brains were observed (Figure 2).



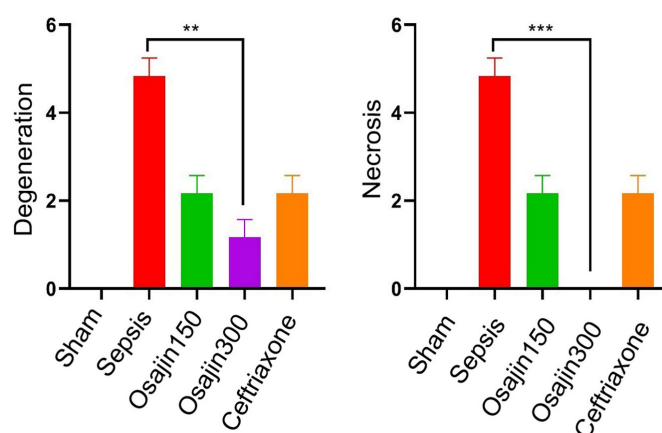
**Figure 2.** Photomicrography of histopathological and immunohistochemical assessment of brain tissues

H&E: Hematoxylin and eosin, 8-OHdG: 8-hydroxydeoxyguanosine, IHC-P, Bar: 50µm

**Sepsis group:** Hyperemia and inflammation were observed in the meningeal and interstitial vessels, whereas severe degeneration and necrosis were observed in the neurons (Figure 2).

**Osajin150 group:** Moderate degeneration and mild necrosis were observed in the neurons and moderate hyperemia was detected in the vessels.

**Osajin300 group:** Mild degeneration of the neurons and hyperemia of the vessels were observed in the brain tissues (Figure 2). In addition, the results were supported by statistical analysis, in which osajin administration at a dose of 300 mg/kg resulted in a significant decrease in necrosis ( $p < 0.001$ ) and degeneration ( $p = 0.0022$ ) compared with the sepsis group (Figure 3).



**Figure 3.** Statistical analysis results of histopathological findings in brains of septic rats

The results are presented as mean  $\pm$  standard deviation, degeneration (\*\* $p = 0.0022$ ), necrosis (\*\* $p < 0.001$ )

**Ceftriaxone group:** Moderate degeneration, mild necrosis of the neurons, and moderate hyperemia of the vessels were observed in the brain tissues (Figure 2).

Statistical results of the histopathological findings are presented in Figure 3 after conducting the appropriate analyses.

### Immunohistochemical Evaluation

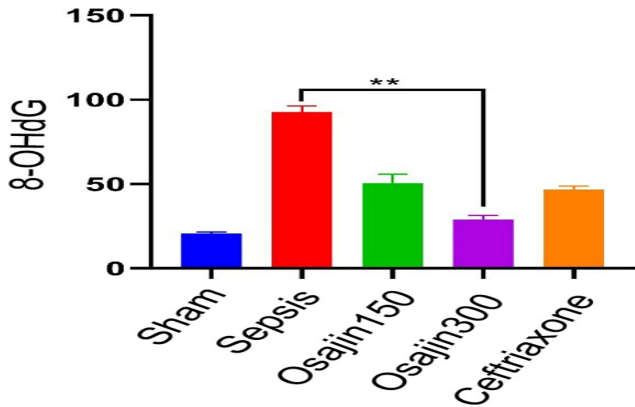
The histopathological findings were supported by the immunohistochemical evaluation of 8-OHdG expression in histological sections of the rat brains. The results for the different groups are as follows:

**Sham group:** 8-OHdG expression was negative in the brain tissues (Figure 2).

**Sepsis group:** High levels of 8-OHdG expression were detected in the cytoplasm of the neurons (Figure 2).

**Osajin150 group:** Moderate expression of cytoplasmic 8-OHdG was evident in the neurons (Figure 2).

**Osajin300 group:** Mild expression of cytoplasmic 8-OHdG was detected in the neurons (Figure 2). Statistical analysis indicated that osajin administration resulted in a significant decrease in 8-OHdG levels ( $28.12 \pm 3.05$ ) ( $p = 0.0022$ ) for this group compared with the sepsis group ( $90.14 \pm 3.75$ ) (Figure 4).



**Figure 4.** Statistical analysis results of 8-OHdG expression in brains of septic rats

The results are presented as mean±standard deviation, \*\*p=0.0028. 8-OHdG: 8-hydroxydeoxyguanosine

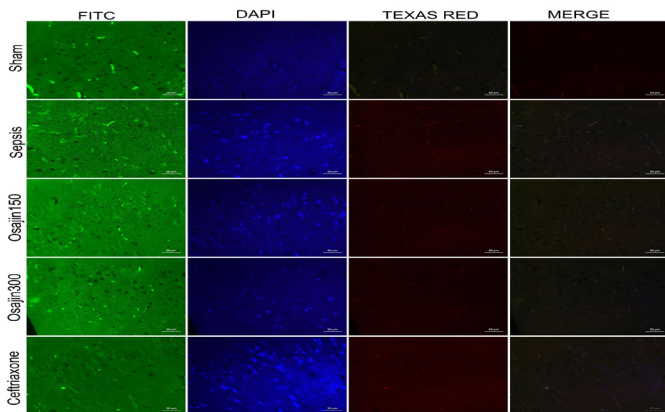
**Ceftriaxone group:** Moderate expression of cytoplasmic 8-OHdG was detected in the neurons (Figure 2).

Statistical results of immunohistochemical evaluation are presented in Figure 4 after conducting the appropriate analysis.

**Double Immunofluorescence Evaluation**

The immunofluorescence evaluation of Bax and caspase-3 expression in the brain tissues was performed to strengthen the conclusions of this study. The results of the different groups are as follows:

**Sham group:** Bax and caspase-3 expression was negative in the brain tissues of this group (Figure 5).



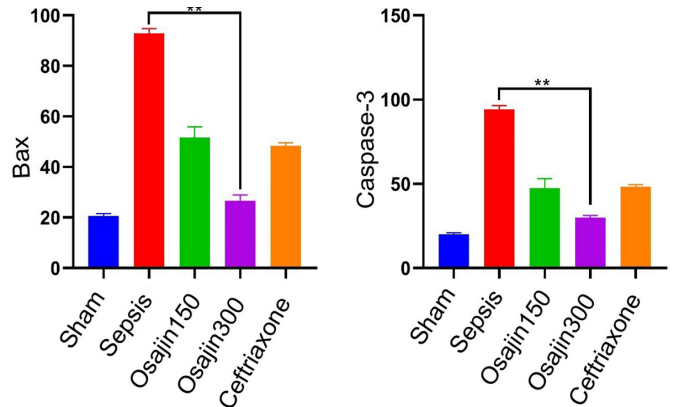
**Figure 5.** Double immunofluorescence results of cytoplasmic Bax (FITC) and caspase-3 (TEXAS RED) in neurons

Bax: Bcl-2-associated protein. IF, Bar: 50µm

**Sepsis group:** Strong expression of Bax and caspase-3 was detected in the cytoplasm of the neurons (Figure 5).

**Osajin150 group:** Moderate cytoplasmic Bax and caspase-3 expression were observed in the neurons of the brain tissues for this group (Figure 5).

**Osajin300 group:** When the brain tissues for this group were examined by immunofluorescence, mild cytoplasmic Bax and caspase-3 expression were detected in the neurons (Figure 5). A significant reduction in Bax (25.55±2.50) and caspase-3 (29.78±2.57) (p=0.0022) levels was reported for this group compared with the sepsis group (90.54±3.08, 94.83±3.84 respectively) (Figure 6).



**Figure 6.** Statistical analysis results of cytoplasmic Bax and caspase-3 expressions in brains of septic rats

The results are presented as mean±standard deviation, Bax (\*\*p=0.0028) and caspase-3 (\*\*p=0.0022). Bax: Bcl-2-associated protein

**Ceftriaxone group:** Ceftriaxone administration caused moderate expression of cytoplasmic Bax and caspase-3 in the neurons (Figure 5).

Figure 6 shows the statistical analysis of the double immunofluorescence evaluation for all groups.

**DISCUSSION**

The present study is the first to evaluate the neuroprotective effects of the natural product osajin, an isoflavone isolated from the fruit of *Maclura pomifera*, against sepsis-induced brain damage. The results provide insight into its therapeutic potential for reducing the burden of brain damage on septic patients. The immunohistochemical and immunofluorescence results highlight the role of the 8-OHdG/Bax/caspase-3 pathway in the promotion of brain injury and reveal the ability of osajin to suppress the components of this pathway in brain tissues.

Of the four nucleotides comprising DNA, guanine is the most susceptible to hydroxylation by hydroxyl radicals because it is the lowest nucleobase in terms of redox capacity.<sup>15</sup> 8-OHdG, which is the first component of the targeted pathway in the present study, is formed following an attack by a hydroxyl radical at the C8 position.<sup>13</sup> Elevated levels of 8-OHdG are an indicator of oxidative damage to DNA or oxidative stress,<sup>16</sup> which occurs from increased levels of reactive oxygen species (ROS) during sepsis.<sup>17</sup> Increased 8-OHdG levels in brain tissues are clear evidence that DNA in the neurons is exposed to damage resulting from excessive ROS production and the collapse of the antioxidant system. Increased expression of 8-OHdG in the serum and brain tissues of LPS-induced septic rats has been reported.<sup>18</sup> Lorente et al.<sup>17</sup> found an association between oxidative DNA damage and mortality and lipid peroxidation in septic patients and suggested serum 8-OHdG as a biomarker for predicting mortality and as a potential target for treating sepsis patients with antioxidant agents. The antioxidant activity of osajin prompted us to investigate its effects in the present study. Osajin reversed the negative effects of the CLP procedure on 8-OHdG expression in brain tissue. Thus, it represents a promising therapeutic agent that can protect genetic material from brain cell damage during sepsis and prevent SEA. Although there are few studies on the

effect of osajin on 8-OHdG expression in brain tissue during sepsis, a study conducted by Alhilal et al.<sup>13</sup> in renal tissue during sepsis supports our findings.

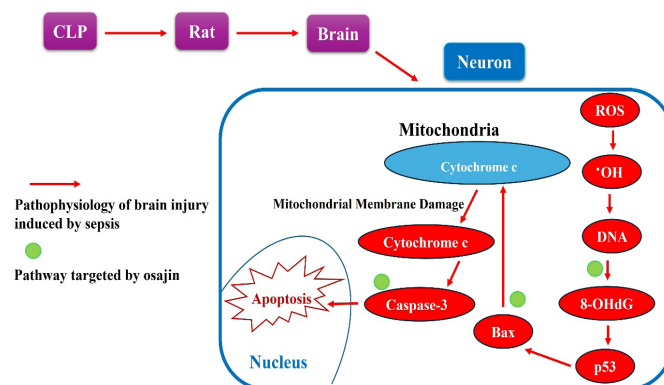
The second component of the pathway targeted in the present study was Bax, which is a pro-apoptotic mediator. It was assessed in brain tissue to evaluate mitochondrial damage and the progression of apoptosis. During cellular homeostasis, Bax is present in the cytosol in an inactive state.<sup>19</sup> It is activated by various cellular signals, such as p53-mediated stimulation following DNA damage.<sup>20</sup> In this context, the importance of assessing 8-OHdG levels is an important component of the pathway targeted in the present study. Activated Bax enters the mitochondrial membrane and becomes an integral membrane protein that forms channels and causes gaps in the mitochondrial membrane to permit the release of cytochrome c, which weakens the membrane and activates pro-apoptotic caspases.<sup>19-21</sup> Therefore, targeting Bax represents an important strategy for reversing apoptosis and disrupting the execution phase of apoptosis. Osajin suppressed this pro-apoptotic mediator and maintained the integrity of the mitochondrial membrane, thus inhibiting apoptosis.

The third component of the pathway is caspase-3. The execution of apoptosis during sepsis is achieved by the activity of the caspases.<sup>22</sup> The most important caspase is caspase-3, which is activated by DNA damage<sup>16,23</sup> or another pathway in the cytosol that leads to an irreversible step in apoptosis by inducing DNA degradation in the nucleus. CLP augmented Bax and apoptosis in the brain tissue of septic rats.<sup>3,24</sup> We examined the role of osajin in suppressing caspase-3. It suppresses caspase-3 through its antioxidant activity by inhibiting DNA damage, which stimulates caspase-3 as the primary executor of apoptosis in neurons. In previous studies, osajin prevented apoptosis during sepsis by inhibiting caspase-3 in hepatic tissue<sup>12</sup> and 8-OHdG and caspase-3 expression in renal tissue.<sup>13</sup> Pomiferin, an isoflavone isolated from *Maclura pomifera* fruits that has a chemical structure similar to osajin, also exerted hepatoprotective effects against apoptosis by reducing caspase-3 and 8-OHdG levels during hepatic injury induced by nickel.<sup>25</sup>

When brain tissues were examined histopathologically, the necrosis of neurons was the predominant histopathological change. This necrosis may be the result of hypoxia in neurons as well as the lethality of ROS to the cellular membranes in the brain resulting from the breakdown of the antioxidant defense system in septic rats. Osajin administration improved the structure of the brain tissues through antioxidant and anti-apoptotic activity.

In summary, brain injury leading to SEA during sepsis occurs as a result of neuronal apoptosis, which develops through the activation of the following sequential pathological mechanisms: 1) Increased ROS levels, particularly hydroxyl radical; 2) Hydroxyl radical-induced DNA lesions; 3) Formation of 8-OHdG as a marker of oxidative DNA damage; 4) 8-OHdG-mediated p53 activation; 5) p53-mediated Bax activation; 6) Mitochondrial damage induced by Bax; 7) Release of cytochrome c from the damaged mitochondrial membrane; 8) Cytochrome c-mediated caspase-3 activation; 9) Apoptosis of neurons; and 10) Brain injury leading to

SEA. This pathological chain was disrupted by targeting its most important cornerstones, 8-OHdG, Bax, and caspase-3, through osajin administration. **Figure 7** shows the proposed pathophysiology of brain injury development in a rat model of sepsis and the pathways targeted by osajin.



**Figure 7.** The proposed pathophysiology of brain injury development in a rat model of sepsis and the pathway targeted by osajin

## Limitations

Undoubtedly, examining p53 and cytochrome c expression in brain tissue would have strengthened the conclusions of this study. These limitations of the present study will be addressed in future studies.

## CONCLUSION

Osajin exhibited protective effects against sepsis-induced brain damage by inhibiting the 8-OHdG/Bax/caspase-3 pathway. These effects were observed at a dose of 300 mg/kg. Accordingly, osajin represents a promising candidate for the treatment of brain tissue damage in septic patients.

## ETHICAL DECLARATIONS

### Ethics Committee Approval

The study was carried out with the permission of the Atatürk University Rectorate Animal Experiments Local Ethics Committee (Date: 01.09.2015, Decision No: 133).

### Informed Consent

Since experimental animals were used in this study, informed consent was not required.

### Referee Evaluation Process

Externally peer-reviewed.

### Conflict of Interest Statement

The authors have no conflicts of interest to declare.

### Financial Disclosure

This study was supported by Atatürk University under the code PRJ2015/298.

### Author Contributions

All of the authors declare that they have all participated in the design, execution, and analysis of the paper, and that they have approved the final version.

## REFERENCES

- Fleischmann C, Scherag A, Adhikari NKJ, et al. Assessment of global incidence and mortality of hospital-treated sepsis current estimates and limitations. *Am J Respir Crit Care Med*. 2016;193(3):259-272. doi:10.1164/rccm.201504-0781OC
- Gofton TE, Young GB. Sepsis-associated encephalopathy. *Nat Rev Neurol*. 2012;8:557-566. doi:10.1038/nrneurol.2012.183
- Gu M, Mei XL, Zhao YN. Sepsis and cerebral dysfunction: BBB damage, neuroinflammation, oxidative stress, apoptosis and autophagy as key mediators and the potential therapeutic approaches. *Neurotox Res*. 2021;39:489-503. doi:10.1007/s12640-020-00270-5
- Krzyżaniak K, Krion R, Szymczyk A, Stepniewska E, Sieminski M. Exploring neuroprotective agents for sepsis-associated encephalopathy: a comprehensive review. *Int J Mol Sci*. 2023;24(13):10780. doi:10.3390/ijms241310780
- Sekino N, Selim M, Shehadah A. Sepsis-associated brain injury: underlying mechanisms and potential therapeutic strategies for acute and long-term cognitive impairments. *J Neuroinflammation*. 2022;19:101. doi:10.1186/s12974-022-02464-4
- Catarina AV, Branchini G, Bettoni L, De Oliveira JR, Nunes FB. Sepsis-associated encephalopathy: from pathophysiology to progress in experimental studies. *Mol Neurobiol*. 2021;58:2770-2779. doi:10.1007/s12035-021-02303-2
- Pan S, Lv Z, Wang R, et al. Sepsis-induced brain dysfunction: pathogenesis, diagnosis, and treatment. *Oxid Med Cell Longev*. 2022;2022:1328729. doi:10.1155/2022/1328729
- Bartošíková L, Nečas J, Suchý V, et al. Protective effects of osajin in ischemia-reperfusion of laboratory rat kidney. *Pharmazie*. 2006;61(6):552-555.
- Florian T, Necas J, Bartosikova L, et al. Effects of prenylated isoflavones osajin and pomiferin in premedication on heart ischemia-reperfusion. *Biomed Pap Med Fac Univ Palacky Olomouc Czech Repub*. 2006;150(1):93-100. doi:10.5507/bp.2006.013
- Cigsar G, Keles ON, Can S, et al. The protective effects of osajin on ischemia/reperfusion injury to rat ovaries: biochemical and histopathological evaluation. *Kafkas Univ Vet Fak Derg*. 2015;21(5):753-760. doi:10.9775/kvfd.2015.13387
- Erol HS, Cakir A, Koc M, Yildirim S, Halici M. Anti-ulcerogenic effect of osajin on indomethacin-induced gastric damage in rats. *Acta Vet Brno*. 2020;89(4):391-400. doi:10.2754/avb202089040391
- Alhilar M, Erol HS, Yildirim S, et al. Osajin from *Maclura pomifera* alleviates sepsis-induced liver injury in rats: biochemical, histopathological and immunohistochemical estimation. *J Taibah Univ Sci*. 2023;17(1):2201250. doi:10.1080/16583655.2023.2201250
- Alhilar M, Erol HS, Yildirim S, et al. Medicinal evaluation and molecular docking study of osajin as an anti-inflammatory, antioxidant, and antiapoptotic agent against sepsis-associated acute kidney injury in rats. *Ren Fail*. 2024;46(2):2379008. doi:10.1080/0886022X.2024.2379008
- Moon HI. Effect of osajin and pomiferin on antidiabetic effects from normal and streptozotocin-induced diabetic rats. *Nat Prod Commun*. 2014;9(12):1723-1724. doi:10.1177/1934578X1400901215
- Ba X, Boldogh Istvan. 8-oxoguanine DNA glycosylase 1: beyond repair of the oxidatively modified base lesions. *Redox Biol*. 2018;14:669-678. doi:10.1016/j.redox.2017.11.008
- Bahar I, Elay G, Başkol G, Sungur M, Donmez-Altuntas H. Increased DNA damage and increased apoptosis and necrosis in patients with severe sepsis and septic shock. *J Crit Care*. 2018;43:271-275. doi:10.1016/j.jcrc.2017.09.035
- Lorente L, Martín MM, González-Rivero AF, et al. Association between DNA and RNA oxidative damage and mortality in septic patients. *J Crit Care*. 2019;54:94-98. doi:10.1016/j.jcrc.2019.08.008
- Dumbuya JS, Chen X, Du J, et al. Hydrogen-rich saline regulates NLRP3 inflammasome activation in sepsis-associated encephalopathy rat model. *Int Immunopharmacol*. 2023;123:110758. doi:10.1016/j.intimp.2023.110758
- Xu J, Lian L, Wu C, Wang X, Fu W, Xu L. Lead induces oxidative stress, DNA damage and alteration of p53, Bax and Bcl-2 expressions in mice. *Food Chem Toxicol*. 2008;46(5):1488-1494. doi:10.1016/j.fct.2007.12.016
- O'Brien MA, Kirby R. Apoptosis: a review of pro-apoptotic and anti-apoptotic pathways and dysregulation in disease. *J Vet Emerg Crit Care*. 2008;18(6):572-585. doi:10.1111/j.1476-4431.2008.00363.x
- Westphal D, Dewson G, Czabotar PE, Kluck RM. Molecular biology of Bax and Bak activation and action. *Biochim Biophys Acta Mol Cell Res*. 2011;1813(4):521-531. doi:10.1016/j.bbamcr.2010.12.019
- Gyawali B, Ramakrishna K, Dhamoon AS. Sepsis: the evolution in definition, pathophysiology, and management. *SAGE Open Med*. 2019;7:1-13. doi:10.1177/2050312119835043
- Dunkern TR, Fritz G, Kaina B. Ultraviolet light-induced DNA damage triggers apoptosis in nucleotide excision repair-deficient cells via Bcl-2 decline and caspase-3/-8 activation. *Oncogene*. 2001;20(42):6026-6038. doi:10.1038/sj.onc.1204754
- Fang J, Lian Y, Xie K, Cai S, Wen P. Epigenetic modulation of neuronal apoptosis and cognitive functions in sepsis-associated encephalopathy. *Neurol Sci*. 2014;35:283-288. doi:10.1007/s10072-013-1508-4
- Deniz GY, Geyikoglu F, Altun S. The regulatory effects of pomiferin dietary on nickel-induced hepatic injury in Sprague-Dawley rats; action mechanisms and signaling pathways. *Toxicol Mech Methods*. 2024;34(5):484-494. doi:10.1080/15376516.2023.2301667